



## The impact of Quercetin Berberine Complex and Clove extract on mice induced asthmatic condition

Roua J. Mohammed 

\*Corresponding author. Department. Of Microbiology, College of Veterinary Medicine, University of Baghdad, Baghdad province, Iraq. E-mail: ruaa.jassem1103a@covm.uobaghdad.edu.iq

---

### *Abstract*

#### **Objective**

Asthma is a chronic inflammatory disorder of the airways described by hyperresponsiveness and constructional remodeling, carried mostly by immune dysregulation. Indigenous combinations as berberine, quercetin, and clove extractive contain well-documented anti-inflammatory and antioxidant attributes. This investigation targeted to survey the immunomodulatory and protective reactions of a quercetin–berberine compound and clove extractive in an ovalbumin (OVA)-induced murine pattern of asthma.

#### **Materials and Methods**

Thirty Swiss mice of both sexes were randomly assigned to three groups (n = 10 per group). The first group obtained an oral dose of quercetin–berberine compound (100 mg/mL, 0.1 mL) once a week for 8 weeks. The second group was given treatment with clove extractive applying the same regimen. The third group acted as a positive control and was managed 10% OVA (0.3 mL, intraperitoneally) on day one and anew after 8 weeks to incite asthma. At the termination of the treatment phase, blood and serum samples were gathered for quantification of white blood cells (WBCs), immunoglobulin E (IgE), and interleukin-4 (IL-4), applying ELISA. All experimental groups were thereafter treated with OVA (0.3 mL, intraperitoneally) before euthanasia at week nine. Histopathological examination of the lungs and trachea was then carried out.

#### **Results**

Treatment with either quercetin–berberine compound or clove extractive meaningfully decreased WBC counts, IL-4, and IgE levels in comparison to the positive control group ( $p \leq 0.05$ ). Histopathological analysis disclosed a marked depletion in airway inflammation, cellular infiltration, and tissue destruction in the treatment groups, denoting an attenuation of OVA-incited

pulmonary pathology. Both treatments revealed equivalent protective reactions, with evidence of restored tissue integrity in comparison to untreated controls.

### Conclusions

The results offer that the quercetin–berberine compound and clove extractive exert potent immunomodulatory activity, alleviating inflammatory responses and tissue destruction in OVA-incited asthma. These outcomes emboss the therapeutic potential of plant-derived combinations as adjunctive or alternative plans in the administration of airway inflammation and asthma. Further investigations are warranted to clarify underlying molecular mechanisms and assess their clinical relevance.

**Keywords:** Asthma, Clove extractive, ELISA, Immune modulation, Ovalbumin

**Paper Type:** Research Paper.

**Citation:** Mohammed, R. J. (2025). The impact of Quercetin Berberine Complex and Clove extract on mice induced asthmatic condition. *Agricultural Biotechnology Journal*, 17(3), 401-422.

---

*Agricultural Biotechnology Journal*, 17(3), 401-422. DOI: 10.22103/jab.2025.25794.1755

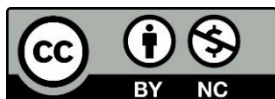Received: June 02, 2025.

Received in revised form: August 25, 2025.

Accepted: August 26, 2025.

Published online: August 30, 2025.

Publisher: Shahid Bahonar University of Kerman & Iranian  
Biotechnology Society.



© the authors

---

### Introduction

Allergic asthma is known as a chronic inflammatory disease of the respiratory tract. This disease described by the infiltration of immune cells as macrophages, lymphocytes, eosinophils, and neutrophils into lung tissue (Dong et al., 2014). Different types of alternative and indigenous treatments, containing herbs and spices, have been studied for asthma administration. Indigenous products are full of bioactive molecules with antibacterial, antioxidant, anti-inflammatory, antidiabetic, and anticancer activities (Jantan et al., 2015; Najafi et al., 2024). In recent years, phytobiotics and medicinal plants have absorbed significant notice as indigenous alternatives to synthetic additives in nutrition (Amirteymoori et al., 2021). These crops include numerous bioactive combinations like essential oils, flavonoids, alkaloids, and phenolic acids, which participate to their antimicrobial, antioxidant, and anti-inflammatory reactions (Jafari Ahmadabadi et al., 2023). Consequently, phytobiotics perform a pivotal task in increasing health,

efficiency, and quality of production (Safaei et al., 2022). The replacement of antibiotics with phytobiotics and medicinal plants in feed supplies various preferences, containing progressed zootechnical performance, suppression of special diseases (Mohammadabadi et al., 2023), antimicrobial and antioxidant functions (Hajalizadeh et al., 2019), hypocholesterolemic reactions, stimulation of digestive enzymes, and progressed liver task (Shokri et al., 2023). Furthermore, phytobiotics modulate gut microbiota, increasing nutrient absorption and immune task (Shahsavari et al., 2023). It has been shown that adding them to diet improves feed intake, increase feed conversion ratios, and raise carcass yield (Vahabzadeh et al., 2020). Moreover, phytobiotics mitigate stress-related impacts, increase meat quality, and decline the environmental footprint of production via optimized nutrient consumption (Mohammadabadi et al., 2024). Given the rising global concerns regarding antibiotic resistance and the request for safer, healthier products, phytobiotics and medicinal plants represent a sustainable and hopeful alternative plan (Mohammadabadi et al., 2022). Between these, quercetin, clove, and berberine are exclusively worth. Clove is famous for its powerful anti-inflammatory and antioxidant functions and has been traditionally applied to raise immune task and alleviate asthma signs (Batiha et al., 2020; Kiki, 2023; Ounaceur et al., 2024). It has been shown to be useful in combating degenerative diseases. (Kiki, 2023). Quercetin is a type of flavonoid that can modulate immune responses and improve asthma. It declines epithelial thickening, mass of smooth muscle, and mast cell degranulation, cuts down IL-4 and Th2 cytokines, and improves Th1 cytokines and IFN- $\gamma$  (Ke et al., 2023). Its antioxidant ability is more increased when mixed with other indigenous molecules, supplying synergistic protection (Ke et al., 2023). Berberine, an isoquinoline alkaloid derived from *Coptis chinensis*, exhibits antioxidant, anti-inflammatory, renal-protective, and neuroprotective attributes in both animal and cellular investigations (Dai et al., 2015; Dong et al., 2015). It prevents pro-inflammatory cytokine production (e.g., IL-6, TNF- $\alpha$ ) and NF- $\kappa$ B activation in lung cells (Lee et al., 2007; Lin et al., 2013; Xu et al., 2013). In OVA-incited asthma patterns, berberine decreased IL-4, IL-5, IL-6, IL-13, and IL-17, emphasizing its role in regulating airway inflammation (Li et al., 2016). Mainly, the mixture of berberine and quercetin exerts synergistic anti-inflammatory reactions in patterns of intestinal inflammation by preventing cytokines like TNF- $\alpha$ , IFN- $\gamma$ , IL-6, and IL-10 (Khater et al., 2022). This synergy has also been apperceived in cancer investigations, where mixtures of quercetin (QUE), curcumin (CUR), and berberine (BBR) suppressed tumor growth, epithelial–mesenchymal transition (EMT), and cancer stemness, exclusively in triple-negative breast cancer patterns (Pandey et al., 2015; Srivastava and Srivastava, 2019; Kashyap et al., 2022). In spite of this hopeful evidence, the potential reactions of the quercetin–berberine compound on asthma stay unknown. Therefore, the current investigation targeted to compare the immunomodulatory and anti-inflammatory activities of the

quercetin–berberine compound with those of clove extractive in an OVA-incited asthma mouse pattern.

## Materials and Methods

**Preparation of Berberine and Quercetin:** Berberine was derived from Double Wood (500 mg dosage), and quercetin was purchased as a dietary supplement from AMAZING AN NUTRITION (500 mg dosage). Both combinations were dissolved and mixed to obtain a combined concentration of 100 mg/mL.

**Preparation of Clove Extractive:** Dried clove buds were purchased from a local herbal store in Baghdad and finely ground into powder applying an electric grinder. A total of eight g of clove powder was suspended in 50 mL of distilled water and stirred overnight applying a magnetic stirrer. The suspension was then filtered via Whatman No. 1 filter paper, and the extractive was stored at 4 °C until applying (Batiha et al., 2020).

**Preparation of Ovalbumin (OVA):** Ovalbumin (98% purity) was purchased from Xi'an Harmonious Natural Biotechnology, China. For sensitization, a 10% OVA solution was prepared and managed intraperitoneally at a volume of 0.3 mL (Al-Saffar & Zalzala, 2023).

**Experimental Design:** Thirty Swiss mice of both sexes were randomly divided into three experimental groups.

- **BQC group:** obtained an oral dose of the quercetin–berberine compound (0.1 mL) once a week for eight weeks.
- **CEG group:** given treatment with clove extractive under the same regimen.
- **OVAG group (positive control):** obtained intraperitoneal injections of OVA (0.3 mL) on the first day of the experiment.

At the termination of the 8-week experimental phase, blood and serum samples were gathered to evaluate WBC count and differential (WBC–CBC+DIFF). Three days later, additional samples were gathered for WBC–CBC+DIFF, as well as IL-4 and IgE measurements.

**IL-4 and IgE Measurement:** Serum levels of IL-4 and IgE were quantified applying commercial ELISA kits particular for mice (Elabscience, China), subsequent the manufacturer's instructions. Absorbance was read at 450 nm applying a microplate reader (Socimed Sarl, France). Concentrations were calculated from standard curves, and outcomes were expressed as pg/mL.

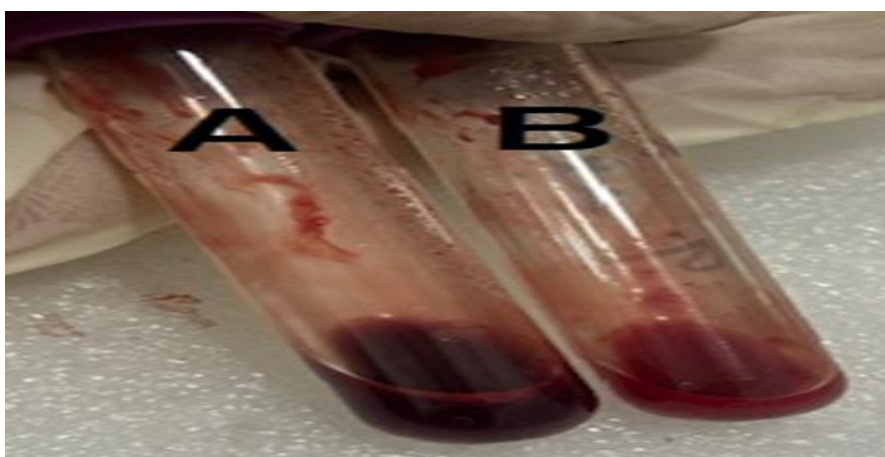
**Histopathological Examination:** Mice were euthanized, and lung and tracheal tissues were excised, rinsed in PBS, and fixed in 10% neutral buffered formalin for 24 h. After fixation, tissues were washed, dehydrated in graded ethanol, cleared with xylene, and embedded in paraffin wax.

Sections were cut, mounted on slides, and stained with hematoxylin and eosin (H&E) for histological evaluation based on Bancroft & Gamble (2007).

**Statistical Analysis:** Data were analyzed applying the Statistical Analysis System (SAS, 2018). Analysis of variance (ANOVA, two-way) was carried out to identify the reactions of treatments. Differences among group means were compared applying the least meaningful difference (LSD) test, with significance set at  $p < 0.05$ .

## Results

**Impact of the quercetin–berberine compound and clove extractive on immune responses:** Blood samples showed that the sensitized group (OVA) exhibited a darker coloration, whereas the given treatment groups demonstrated a bright red appearance (Figure 1A and B). Regarding white blood cell (WBC) counts, a meaningful improve ( $p \leq 0.05$ ) was apperceived in the sensitized mice (OVA), which reached  $15.85 \pm 0.04 \times 10^3/\mu\text{L}$ , in comparison to the given treatment groups QBC and CE, which documented  $8.61 \pm 0.03$  and  $9.42 \pm 0.03 \times 10^3/\mu\text{L}$ , respectively, subsequent OVA sensitization (Table 1). Lymphocyte levels were also markedly elevated in the OVA group ( $10.79 \pm 0.02\%$ ) in comparison to the given treatment groups. In contrast, the given treatment groups (QBC and CE) showed meaningfully lower lymphocyte counts ( $7.03 \pm 0.01\%$  and  $7.37 \pm 0.01\%$ , respectively), both of which stayed meaningfully higher than baseline values prior to sensitization. A meaningful rise in eosinophil counts was also apperceived in the OVA-sensitized group ( $3.83 \pm 0.02\%$ ), whereas the given treatment groups revealed a substantial depletion, with counts of  $0.626 \pm 0.01\%$  and  $1.22 \pm 0.01\%$ , respectively. For monocytes, neutrophils, and basophils, no statistically meaningful differences were found between the given treatment and positive control groups (Table 1).



**Figure 1. (A) Blood sample from positive control (OVA). (B) Blood sample from given treatment groups**

**Table 1. Hematological parameters in experimental groups**

Parameter (unit)	QBC	QBC+OVA	CE	CE+OVA	OVA	<i>p</i> -value
WBC ( $\times 10^3/\mu\text{L}$ )	8.39 $\pm$ 0.01 <sup>b</sup>	8.61 $\pm$ 0.03 <sup>b</sup>	9.65 $\pm$ 0.02 <sup>b</sup>	9.42 $\pm$ 0.03 <sup>b</sup>	15.85 $\pm$ 0.04 <sup>a</sup>	0.002
Neutrophils (%)	0.316 $\pm$ 0.005	0.342 $\pm$ 0.006	0.420 $\pm$ 0.003	0.348 $\pm$ 0.011	0.638 $\pm$ 0.008	NS
Lymphocytes (%)	6.47 $\pm$ 0.01 <sup>b</sup>	7.03 $\pm$ 0.01 <sup>b</sup>	6.62 $\pm$ 0.01 <sup>b</sup>	7.37 $\pm$ 0.01 <sup>b</sup>	10.79 $\pm$ 0.02 <sup>a</sup>	0.018
Monocytes (%)	0.436 $\pm$ 0.009	0.458 $\pm$ 0.012	0.422 $\pm$ 0.008	0.338 $\pm$ 0.006	0.436 $\pm$ 0.008	NS
Eosinophils (%)	1.02 $\pm$ 0.01 <sup>bc</sup>	0.626 $\pm$ 0.01 <sup>c</sup>	2.02 $\pm$ 0.01 <sup>b</sup>	1.22 $\pm$ 0.01 <sup>bc</sup>	3.83 $\pm$ 0.02 <sup>a</sup>	0.001
Basophils (%)	0.148 $\pm$ 0.02	0.156 $\pm$ 0.01	0.166 $\pm$ 0.01	0.142 $\pm$ 0.01	0.166 $\pm$ 0.01	NS

*p*-values were derived applying repeated-calculates ANOVA. A significance threshold of  $p \leq 0.05$  was applied; Different superscript letters (a, b, c) within the same row illustrate meaningful differences among groups; NS = Not meaningful.

**IL-4 concentrations in experimental groups:** The analysis of IL-4 concentrations disclosed meaningful alters among the different groups. Both the quercetin–berberine compound (G1) and clove extractive (G2) groups showed a marked improve in IL-4 levels at eight weeks in comparison to baseline values ( $p < 0.05$ ) (Table 2). Similarly, the OVA control group (G3) exhibited a meaningful elevation in IL-4 concentrations ( $p \leq 0.05$ ) at eight weeks, reflecting the reaction of OVA sensitization on day 1. At 9 weeks post-OVA sensitization, Group 3 (OVA) demonstrated the highest IL-4 levels, reaching  $1894.08 \pm 14.30$  pg/mL. Although the treatment groups also revealed meaningful improves at this time point ( $719.13 \pm 20.61$  pg/mL for G1 and  $809.53 \pm 20.28$  pg/mL for G2), their values stayed substantially lower than those of the positive control group (Table 2).

**IgE concentrations in experimental groups:** The evaluation of IgE concentrations disclosed meaningful alters across all experimental groups (G1, G2, and G3). Both the quercetin–berberine compound (G1) and clove extractive (G2) groups exhibited a meaningful improve in IgE levels at 8 weeks in comparison to baseline values ( $p \leq 0.05$ ) (Table 3). In the OVA control group (G3), which acted as the positive control, IgE concentrations rose sharply at week 8, reaching  $2095.73 \pm 23.20$  pg/mL ( $p \leq 0.05$ ), subsequent OVA sensitization on day 1. At 9 weeks post-sensitization, Group 3 documented the highest IgE levels, with values of  $4894.08 \pm 14.39$  pg/mL. Although IgE levels in the given treatment groups also improved at 9 weeks ( $1719.14 \pm 20.61$  pg/mL for G1 and  $1809.53 \pm 20.28$  pg/mL for G2), these concentrations stayed markedly lower than those apperceived in the positive control group (Table 3).

**Table 2. IL-4 concentrations in mice given treatment with the quercetin–berberine compound and clove extractive, calculated applying ELISA**

Group (n = 10)	Zero Day (Baseline)	8 Weeks (Before OVA Sensitization)	L.S.D.	9 Weeks (After OVA Sensitization)	L.S.D.
<b>G1: Quercetin–Berberine Compound (QBC)</b>	34.98 ± 0.97 A <sup>a</sup>	414.75 ± 22.32 A <sup>b</sup>	52.905 *	719.13 ± 20.61 C <sup>a</sup>	52.905 *
<b>G2: Clove Extractive (CE)</b>	35.37 ± 0.54 A <sup>c</sup>	312.01 ± 19.08 B <sup>b</sup>	48.486 *	809.53 ± 20.28 B <sup>a</sup>	48.486 *
<b>G3: OVA Control (Positive Control)</b>	30.93 ± 0.62 B <sup>c</sup>	165.73 ± 20.74 C <sup>b</sup>	43.945 *	1894.08 ± 14.30 A <sup>a</sup>	43.945 *

Data are shown as mean ± SE (pg/mL); L.S.D. = Least Significant Difference for comparisons between groups at each time point; Different capital letters (A, B, C) within the same column illustrate meaningful differences among groups at the same time point; Different lowercase letters (<sup>a</sup>, <sup>b</sup>, <sup>c</sup>) within the same row illustrate meaningful differences within the same group over time;  $p \leq 0.05$  was attended statistically meaningful; NS = Not meaningful.

**Histopathological alters in the lung and trachea:** After one week of OVA sensitization, histological examination disclosed separate pathological alterations in the trachea and lungs of the test groups as well as the positive control group.

**G1 (Quercetin–Berberine Compound, QBC):** Tracheal histopathology showed inflammatory cell infiltration into the subepithelium and lumen (red arrows), along with evidence of epithelial injury or desquamation. Yellow stars illustrated glandular components and connective tissue (Figure 2). Mononuclear inflammatory cell aggregates, likely lymphocytes or macrophages, were apperceived (red arrows), whereas individual epithelial cells, possibly neutrophils or eosinophils, were noted (black arrows). Improve d mucus secretion and epithelial shedding were also apparent (yellow star) (Figure 3). In the lungs, tubular dilatation and epithelial degeneration were evident, with proteinaceous casts within the tubular lumina (yellow stars), accompanied by interstitial infiltration of mononuclear cells in line with chronic inflammation (Figure 4). Destructed epithelial cells were also noted (black arrows). Overall, the lung architecture revealed preserved alveolar structures interspersed with inflammatory foci, showing mild peribronchial and perivascular inflammation, while alveolar airspaces stayed intact (Figure 5). More severe lesions included gross peribronchial inflammatory infiltration and thickened alveolar septa, indicative of edema or chronic inflammation, involving mixed inflammatory cells like lymphocytes, eosinophils, and macrophages (Figure 6).

**G2 (Clove Extractive, CE):** Histological examination disclosed hyperplasia of the bronchiolar epithelium with goblet cell metaplasia, characteristic of allergic airway inflammation. Mild epithelial thickening and subepithelial inflammatory infiltration were apperceived, along with slight thickening of the basement membrane (Figure 7). The lamina propria included

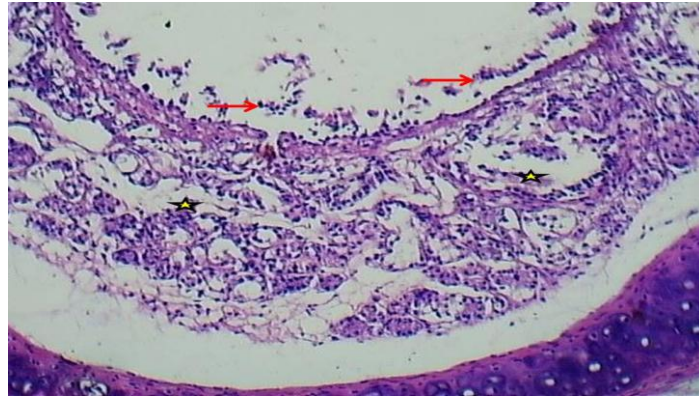
mononuclear cell-rich infiltrates (starred areas), with epithelial alters like possible basal cell hyperplasia and mild edema of connective tissue (Figure 8). The alveolar architecture stayed mostly preserved, though peribronchial and perivascular infiltration was evident but less intense compared to the positive control. Occasional thickening of alveolar septa, vascular congestion, and scattered inflammatory foci were noted (Figure 9). Alveolar spaces were partially preserved, with mild interstitial mononuclear infiltration, alongside perivascular and peribronchial inflammatory cell accumulations (Figure 10).

**Table 3. IgE concentrations in mice given treatment with the quercetin–berberine compound and clove extractive, calculated applying ELISA**

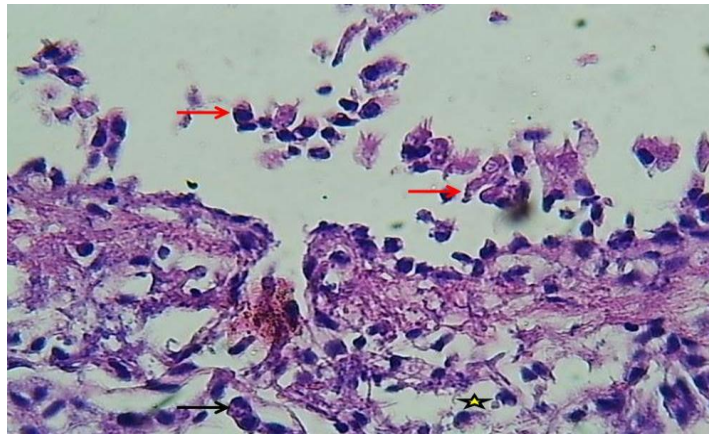
Group (n = 10)	Zero Day (Baseline)	8 Weeks (Before OVA Sensitization)	L.S.D.	9 Weeks (After OVA Sensitization)	L.S.D.
<b>G1: Quercetin–Berberine Compound (QBC)</b>	126.48 ± 1.53 A <sup>c</sup>	664.75 ± 37.26 C <sup>b</sup>	74.154 *	1719.14 ± 20.61 C <sup>a</sup>	74.154 *
<b>G2: Clove Extractive (CE)</b>	125.37 ± 0.54 A <sup>c</sup>	912.01 ± 20.44 B <sup>b</sup>	50.13 *	1809.53 ± 20.28 B <sup>a</sup>	50.13 *
<b>G3: OVA Control (Positive Control)</b>	122.59 ± 0.19 A <sup>c</sup>	2095.73 ± 23.20 A <sup>b</sup>	47.564 *	4894.08 ± 14.39 A <sup>a</sup>	47.564 *
<b>L.S.D. value</b>	4.513 NS	84.273 *	—	56.213 *	—

Data are shown as mean ± SE (pg/mL); L.S.D. = Least Significant Difference for comparisons between groups at each time point; Different capital letters (A, B, C) within the same column illustrate meaningful differences among groups at the same time; Different lowercase letters (a, b, c) within the same row illustrate meaningful differences within the same group over time;  $p \leq 0.05$  was attended statistically meaningful; NS = Not meaningful.

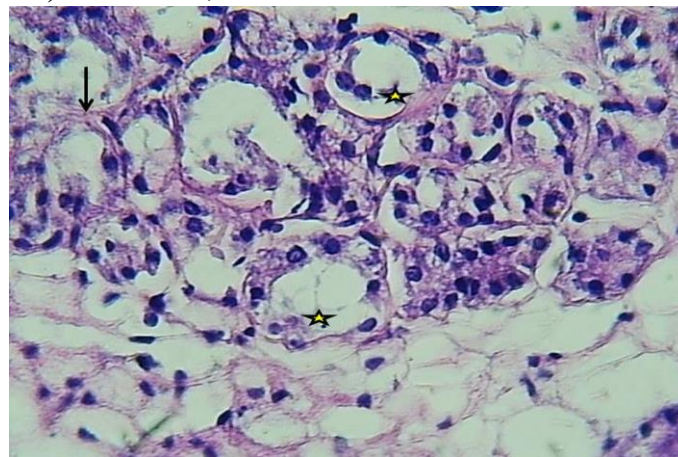
**G3 (OVA Control, Positive Control):** Histopathological analysis disclosed dense perivascular and peribronchial inflammatory cell infiltration, predominantly composed of eosinophils and lymphocytes (Figures 11–14). Tracheal mucosa showed marked thickening, epithelial hyperplasia (black arrows), and degeneration of submucosal tracheal glands accompanied by infiltration of mononuclear leukocytes (asterisks) (Figure 11). Similar mucosal thickening and epithelial hyperplasia were noted in Figure 12, along with degeneration of acinar glandular cells and mononuclear leukocyte infiltration (asterisks). Subepithelial fibrosis or smooth muscle hypertrophy was suspected, with congested bronchi (labeled “b”) and alveolar airspaces (labeled “a”), including exudates and inflammatory infiltrates (asterisks) (Figure 13). Additional lesions included excessive mucus production, in line with chronic asthma pathology, as well as lymphoid hyperplasia with bronchus-related lymphoid follicles (Figure 14). A comparative histopathological evaluation of tracheal and lung lesions across all groups is shown in Figure 15.



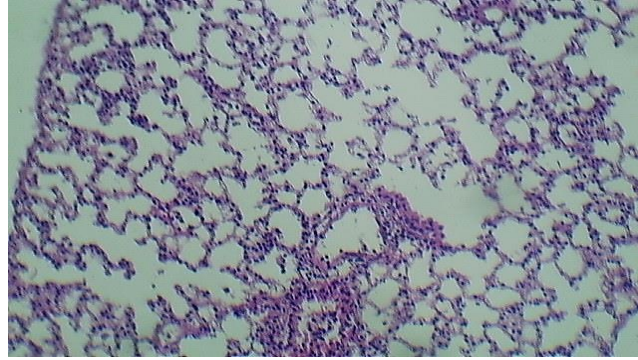
**Figure 2.** Section of trachea (G1) showing inflammatory cell infiltration into the subepithelium and lumen (red arrows), glandular components and connective tissue (yellow stars), and probable epithelial injury or desquamation. H&E stain, 10X.



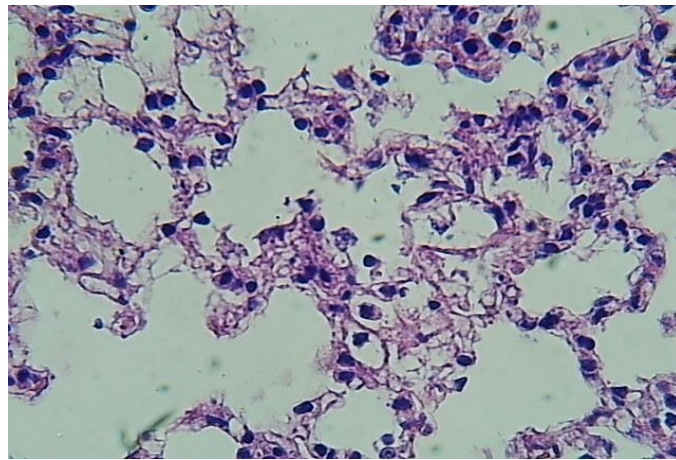
**Figure 3.** Section of trachea (G1) showing aggregates of mononuclear inflammatory cells (red arrows; likely lymphocytes or macrophages), single epithelial cells or possible neutrophils/eosinophils (black arrow), and improved mucus secretion with epithelial shedding (yellow star). H&E stain, 40X.



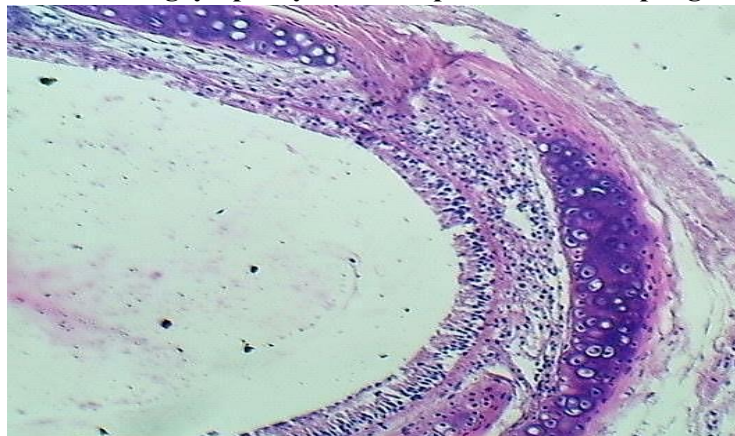
**Figure 4.** Section of trachea (G1) showing tubular dilatation, epithelial flattening and degeneration, proteinaceous casts in tubular lumina (yellow stars), and interstitial infiltration by mononuclear cells. H&E stain, 40X.



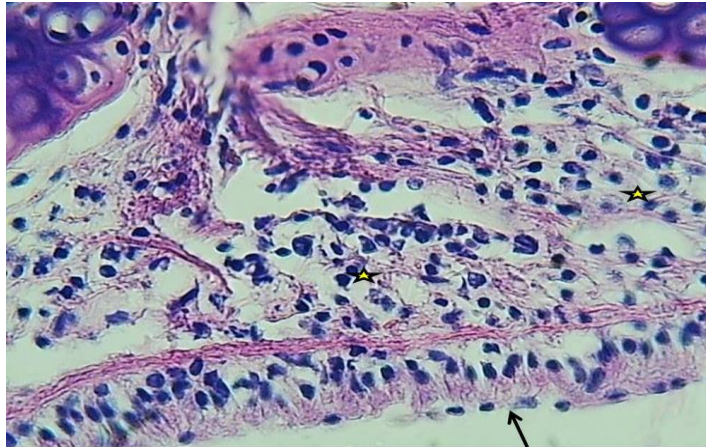
**Figure 5.** Section of lung (G1) showing injured epithelial cells (black arrow). The lung holds normal alveolar architecture with mild peribronchial and perivascular inflammatory clusters. H&E stain, 10X.



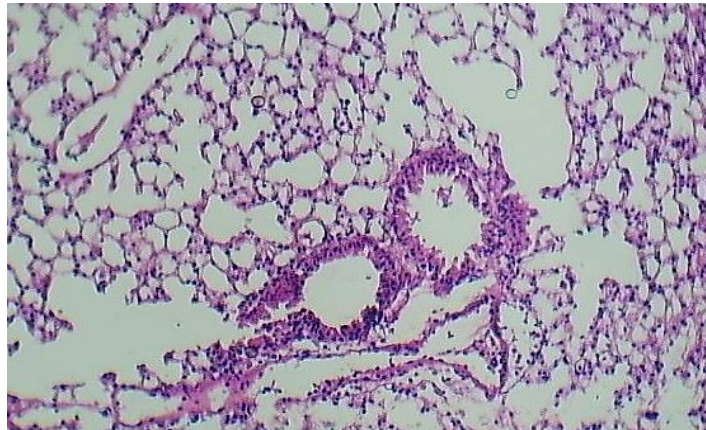
**Figure 6.** Section of lung (G1) showing gross peribronchial infiltration by inflammatory cells, thickened alveolar septa indicative of edema or chronic inflammation, with mixed inflammatory cells containing lymphocytes, eosinophils, and macrophages. H&E stain, 40X.



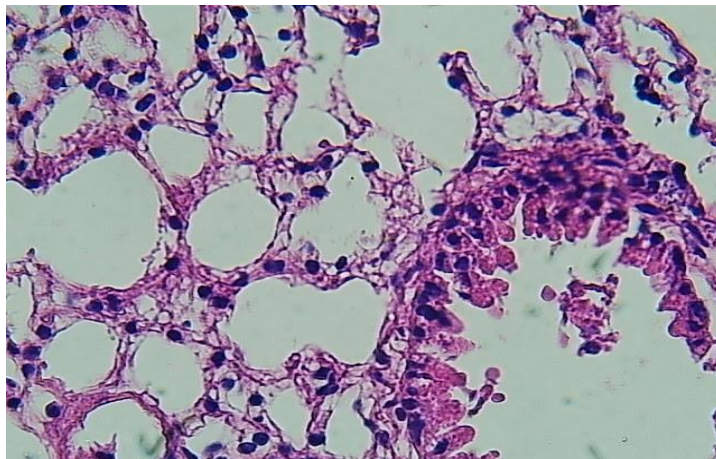
**Figure 7.** Section of trachea (G2) showing hyperplastic bronchiolar epithelium, goblet cell metaplasia, mild epithelial thickening, subepithelial inflammatory infiltration, and slight thickening of the basement membrane. H&E stain, 10X.



**Figure 8. Section of trachea (G2) showing mononuclear cell-rich inflammatory infiltrates in the lamina propria (starred areas), epithelial alters offering basal cell hyperplasia (arrow), and mild connective tissue edema. H&E stain, 40X.**



**Figure 9. Section of lung (G2) showing occasional thickening of alveolar septa, scattered interstitial inflammatory foci, mild cellular infiltration, and focal vascular congestion. H&E stain, 10X.**



**Figure 10. Section of lung (G2) showing partially preserved alveolar spaces, mild interstitial mononuclear cell infiltration, and cellular infiltration in perivascular and peribronchial areas. H&E stain, 40X.**

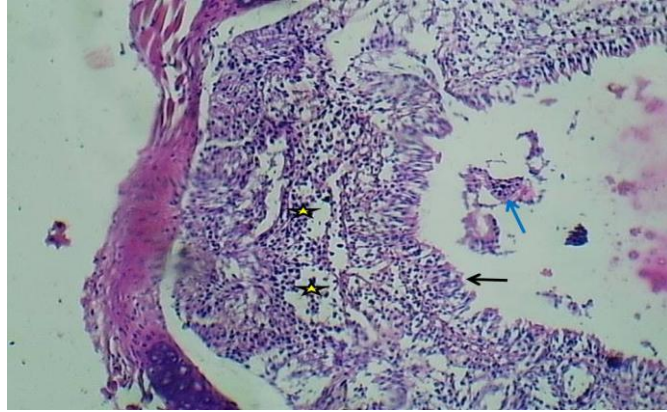


Figure 11. Section of trachea (G3) showing marked mucosal thickening with epithelial hyperplasia (black arrow), submucosal degeneration of tracheal glands, and mononuclear leukocyte infiltration (asterisks). H&E stain, 10X.

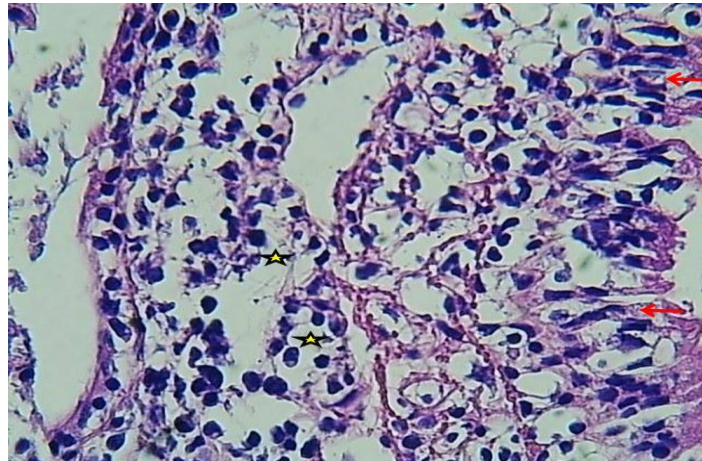
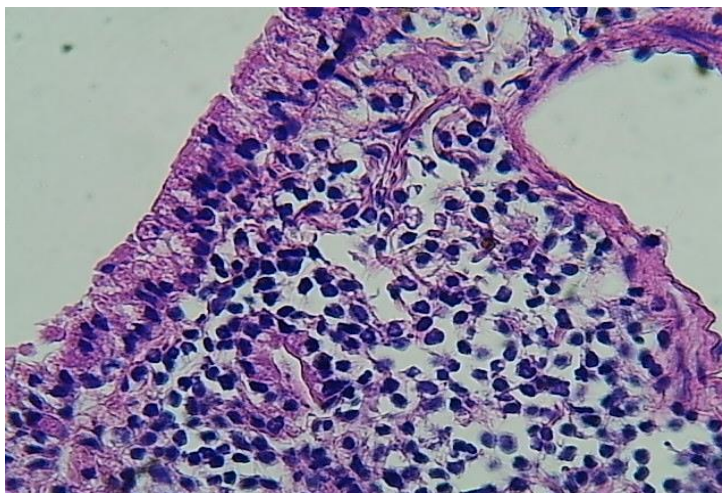


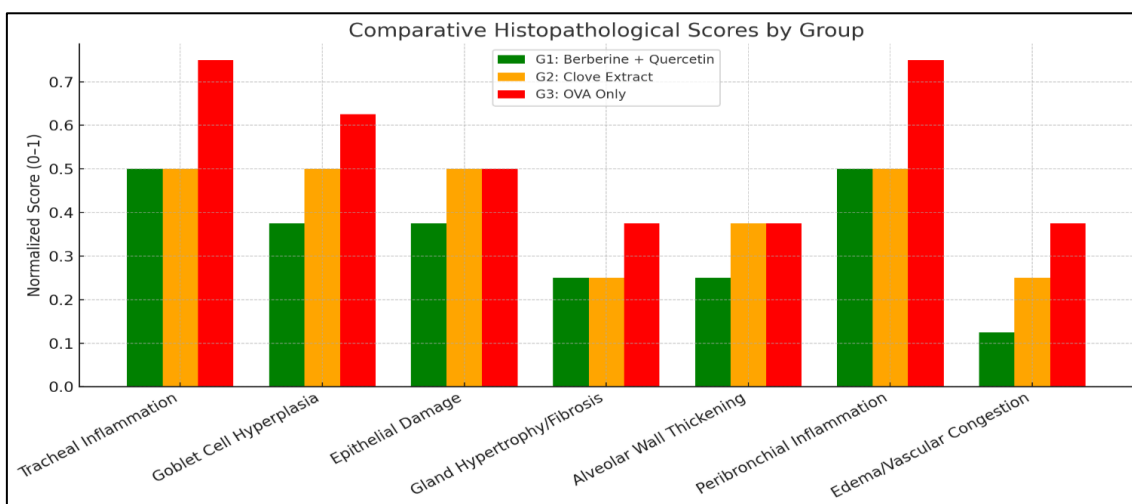
Figure 12. Section of trachea (G3) showing mucosal thickening, epithelial hyperplasia (arrows), submucosal degeneration of acinar gland cells, and mononuclear leukocyte infiltration (asterisks). H&E stain, 40X.

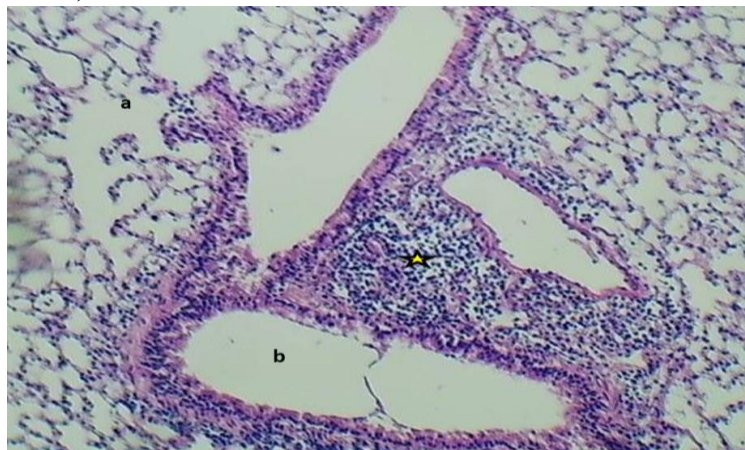

Figure 13. Section of lung (G3) showing suspected subepithelial fibrosis or smooth muscle thickening, congested bronchi (labeled “b”), alveolar airspaces (labeled “a”), and focal exudates with inflammation (asterisk). H&E stain, 10X.



**Figure 14.** Section of lung (G3) showing normal bronchial epithelium with reactive lymphoid hyperplasia and bronchus-related lymphoid follicles. H&E stain, 40X.



**Figure 15.** Comparative histopathological analysis of lung and tracheal lesions across all experimental groups

**Discussion**

**Impact of Quercetin–Berberine Compound and Clove Extractive on Immune Response:** Asthma is a chronic inflammatory disease primarily carried by T-helper 2 (Th2) cells, leading to the secretion of IgE, IL-4, IL-5, and IL-13, which create airway inflammation and eosinophilic infiltration (Askari et al., 2020). Ovalbumin (OVA), a broadly applied allergen in animal patterns, elicits strong Th2-type immune responses that closely mimic human asthma (Kim et al., 2022). In the current investigation, OVA-sensitized mice (G3) exhibited typical features of allergic airway inflammation, containing elevated WBC, lymphocyte, and eosinophil counts; high IL-4 and IgE levels; and extensive histopathological alters in lung and tracheal

tissues. In contrast, mice pretreated with the quercetin–berberine compound (QBC, G1) or clove extractive (CE, G2) revealed meaningfully decreased inflammatory markers and attenuated histopathological destruction, although full restoration of tissue architecture was not achieved. These results illustrate that both indigenous agents confer partial immunoprotective reactions in allergic asthma.

**Mechanistic Discernments:** The protective reactions of QBC and CE may involve different mechanisms:

- **Th2 Cytokine Suppression:** Both treatments meaningfully decreased IL-4 and IgE production, the primary mediators of Th2 responses and B-cell activation.

- **Eosinophil Modulation:** QBC and CE markedly decreased eosinophil counts, offering prevention of chemotactic signals like eotaxin and IL-5.

- **NF-κB Pathway Inhibition:** Berberine and eugenol have been shown to prevent NF-κB activation, a key regulator of pro-inflammatory gene expression (Pan & Dong, 2015).

- **Antioxidant Activity:** Quercetin and clove extractive contain potent antioxidant attributes that protect the airway epithelium from oxidative destruction and preserve tissue integrity.

These results are in line with previous reports. Pan and Dong (2015) revealed that eugenol suppressed IL-4/IL-5 production, eosinophilia, and NF-κB activity in allergic asthma patterns. Oliveira et al. (2015) announced that quercetin combined with *Allium cepa* extractive prevented eosinophil activity and IgE production. Other investigations have affirmed the anti-inflammatory and airway-protective reactions of berberine and clove extractive in OVA-incited asthma (Li et al., 2016). Collectively, these results support the anti-inflammatory, antioxidant, and immunomodulatory roles of these phytochemicals in asthma therapy.

**Histopathological Alters in Lung and Trachea- G1 (QBC + OVA):** Histopathology disclosed mild tracheal inflammation, goblet cell hyperplasia, epithelial desquamation, and lymphocytic and eosinophilic infiltration. Lung tissue exhibited mild to moderate inflammation with partial preservation of alveolar architecture. QBC treatment decreased airway inflammation compared to OVA alone, denoting partial effectiveness. Previous investigations support these observations, showing that berberine suppresses NF-κB, IL-4, and IL-5, thereby preventing eosinophilic inflammation (Li et al., 2016), while quercetin attenuates Th2 cytokine production and eosinophil recruitment via antioxidant and anti-inflammatory mechanisms (Rogerio et al., 2010). These combinations likely act synergistically to prevent allergic inflammation.

**G2 (CE + OVA):** The lung architecture was mostly preserved, with minimal peribronchial and perivascular inflammation, goblet cell metaplasia, and negligible alveolar septal thickening. CE conferred moderate protection by reducing tissue destruction and inflammatory cell

infiltration. Eugenol, the principal bioactive component of clove, has been shown to prevent COX-2, IL-5, and histamine release, while its antioxidant attributes protect airway tissue (Kamatou et al., 2012).

**G3 (OVA Control):** Dense perivascular and peribronchial inflammatory infiltrates (predominantly eosinophils and lymphocytes), goblet cell hyperplasia, epithelial thickening, congestion, and lymphoid follicle expansion were apperceived. These results reflect classic features of chronic allergic airway inflammation, validating the asthma pattern. OVA-incited asthma patterns are described by elevated Th2 cytokines, IgE levels, and airway remodeling (Temelkovski et al., 1998).

**Limitations and Future Directions:** Although QBC and CE generated meaningful improvements, neither treatment completely normalized immune parameters or tissue architecture. Further study is needed to:

- Clarify molecular pathways, containing IL-13, STAT6, and TSLP signaling.
- Identify optimal dosing and timing for maximum effectiveness.
- Survey potential synergism with conventional therapies like corticosteroids.
- Evaluate long-term reactions and translational potential in human asthma.

**Conclusions:** The quercetin–berberine compound and clove extractive exhibit meaningful immunomodulatory and anti-inflammatory reactions in a murine OVA-incited asthma pattern. Treatment with these agents decreased WBC counts, IL-4, IgE, and eosinophil levels, and attenuated histopathological alters in lung and trachea. These indigenous products represent hopeful complementary therapies for allergic asthma via modulation of Th2-mediated immune responses, although further investigations are required to optimize their clinical utilization.

### Authors' Contributions

Roua Jassim Mohammed: Conceptualization, Methodology, Validation, Formal analysis, Investigation, Resources, Data curation, Writing – original draft preparation, Writing – review and editing, Visualization, Supervision, Project administration. The author has read and approved the terminal version of the manuscript.

### Data Availability

Not applicable.

### Acknowledgments

This investigation was not supported by any special grant from funding organizations in the public, commercial, or non-profit sectors

### Ethical considerations

Ethical approval was granted via the local committee of animal care and apply at the College of Veterinary Medicine within the University of Baghdad (Number P-G\434,19\2\2025) through this investigation. This study does not involve any clinical trials and did not involve human participants, and therefore, informed consent was not needed.

### Funding

This investigation did not obtain any special funding from public, commercial, or nonprofit organizations.

### Conflicts of Interest

The authors declare no conflicts of interest.

### References

- Al-Saffar, H., & Zalzal, N. M. H. (2023). The possible protective effect of cinnamic acid on ovalbumin-induced asthma in mice. *Iraqi Journal of Pharmaceutical Sciences*, 32(1), 133–138. <https://doi.org/10.31351/vol32iss1pp133-138>
- Amirteymoori, E., Khezri, A., Dayani, O., Mohammadabadi, M., Khorasani, S., Mousaie, A., & Kazemi-Bonchenari, M. (2021). Effects of linseed processing method (ground versus extruded) and dietary crude protein content on performance, digestibility, ruminal fermentation pattern, and rumen protozoa population in growing lambs. *Italian Journal of Animal Science*, 20(1), 1506–1517. <https://doi.org/10.1080/1828051X.2021.1984324>
- Askari, V. R., Alavinezhad, A., Rahimi, V. B., Rezaee, S. A., & Boskabady, M. H. (2021). Immuno-modulatory effects of methanolic extract of *Ferula szowitsiana* on isolated human Th1/Th2/Treg cytokines levels, and their genes expression and nitric oxide production. *Cytokine*, 138, Article 155387. <https://doi.org/10.1016/j.cyto.2020.155387>
- Bancroft, J. D., & Gamble, M. (2007). *Theory and practice of histological techniques* (6th ed.). Churchill Livingstone.
- Batiha, G. E., Alkazmi, L. M., Wasef, L. G., Beshbishy, A. M., Nadwa, E. H., & Rashwan, E. K. (2020). *Syzygium aromaticum* L. (Myrtaceae): Traditional uses, bioactive chemical constituents, pharmacological and toxicological activities. *Biomolecules*, 10(2), Article 202. <https://doi.org/10.3390/biom10020202>
- Dai, P., Wang, J., Lin, L., Zhang, Y., & Wang, Z. (2015). Renoprotective effects of berberine as adjuvant therapy for hypertensive patients with type 2 diabetes mellitus: Evaluation via


- biochemical markers and color Doppler ultrasonography. *Experimental and Therapeutic Medicine*, 10(3), 869–876. <https://doi.org/10.3892/etm.2015.2585>
- Dong, F., Wang, C., Duan, J., Zhang, W., Xiang, D., & Li, M. (2014). Puerarin attenuates ovalbumin-induced lung inflammation and hemostatic unbalance in rat asthma model. *Evidence-Based Complementary and Alternative Medicine*, 2014, Article 726740. <https://doi.org/10.1155/2014/726740>
- Dong, S. F., Yasui, N., Negishi, H., Kishimoto, A., Sun, J. N., & Ikeda, K. (2015). Increased oxidative stress in cultured 3T3-L1 cells was attenuated by berberine treatment. *Natural Product Communications*, 10(6), 895–897. <https://pubmed.ncbi.nlm.nih.gov/26197511/>
- Hajalizadeh, Z., Dayani, O., Khezri, A., Tahmasbi, R., & Mohammadabadi, M. R. (2019). The effect of adding fennel (*Foeniculum vulgare*) seed powder to the diet of fattening lambs on performance, carcass characteristics, and liver enzymes. *Small Ruminant Research*, 175, 72–77. <https://doi.org/10.1016/j.smallrumres.2019.04.011>
- Jafari Ahmadabadi, S. A. A., Askari-Hemmat, H., Mohammadabadi, M., Asadi Fozi, M., & Mansouri Babhootki, M. (2023). The effect of cannabis seed on DLK1 gene expression in heart tissue of Kermani lambs. *Agricultural Biotechnology Journal*, 15(1), 217–234. <https://doi.org/10.22103/jab.2023.21265.1471>
- Jantan, I., Ahmad, W., & Bukhari, S. N. A. (2015). Plant-derived immunomodulators: An insight on their preclinical evaluation and clinical trials. *Frontiers in Plant Science*, 6, Article 655. <https://doi.org/10.3389/fpls.2015.00655>
- Kamatou, G. P., Vermaak, I., & Viljoen, A. M. (2012). Eugenol—From the remote Maluku Islands to the international market place: A review of a remarkable and versatile molecule. *Molecules*, 17(6), 6953–6981. <https://doi.org/10.3390/molecules17066953>
- Kashyap, A., Umar, S. M., J. R., A. D., Mendiratta, M., & Prasad, C. P. (2022). In vitro anticancer efficacy of a polyphenolic combination of quercetin, curcumin, and berberine in TNBC cells. *Phytomedicine Plus*, 2(2), Article 100265. <https://doi.org/10.1016/j.phyplu.2022.100265>
- Ke, X., Chen, Z., Wang, X., Kang, H., & Hong, S. (2023). Quercetin improves the imbalance of Th1/Th2 cells and Treg/Th17 cells to attenuate allergic rhinitis. *Autoimmunity*, 56(1), Article 2189133. <https://doi.org/10.1080/08916934.2023.2189133>
- Khater, S. I., Lotfy, M. M., Alandiyjany, M. N., Alqahtani, L. S., Zagloul, A. W., Althobaiti, F., Ismail, T. A., Soliman, M. M., Saad, S., & Ibrahim, D. (2022). Therapeutic potential of quercetin loaded nanoparticles: Novel insights in alleviating colitis in an experimental DSS induced colitis model. *Biomedicines*, 10(7), Article 1654. <https://doi.org/10.3390/biomedicines10071654>

- Kiki, M. J. (2023). In vitro antiviral potential, antioxidant, and chemical composition of clove (*Syzygium aromaticum*) essential oil. *Molecules*, 28(6), Article 2421. <https://doi.org/10.3390/molecules28062421>
- Kim, H. J., Song, J. Y., Park, T. I., Choi, W. S., Kim, J. H., Kwon, O. S., & Lee, J. Y. (2022). The effects of BRL-50481 on ovalbumin-induced asthmatic lung inflammation exacerbated by co-exposure to Asian sand dust in the murine model. *Archives of Pharmacal Research*, 45(1), 51–62. <https://doi.org/10.1007/s12272-021-01367-x>
- Lee, C., Chen, J., Hsiang, C., Wu, S., Wu, H., & Ho, T. (2007). Berberine suppresses inflammatory agents-induced IL-1 $\beta$  and TNF- $\alpha$  production via inhibition of I $\kappa$ B degradation in human lung cells. *Pharmacological Research*, 56(3), 193–201. <https://doi.org/10.1016/j.phrs.2007.06.003>
- Li, Z., Zheng, J., Zhang, N., & Li, C. (2016). Berberine improves airway inflammation and inhibits NF- $\kappa$ B signaling pathway in an ovalbumin-induced rat model of asthma. *Journal of Asthma*, 53(10), 999–1005. <https://doi.org/10.1080/02770903.2016.1180530>
- Lin, K., Liu, S., Shen, Y., & Li, Q. (2013). Berberine attenuates cigarette smoke-induced acute lung inflammation. *Inflammation*, 36(5), 1079–1086. <https://doi.org/10.1007/s10753-013-9640-0>
- Mohammadabadi, M., Babenko, O., Borshch, O. O., Kalashnyk, O., Ievstafiiieva, Y., & Buchkovska, V. (2024). Measurement of the relative expression pattern of the UCP2 gene in different tissues of the Raini Cashmere goat. *Agricultural Biotechnology Journal*, 16(3), 317–332. <https://doi.org/10.22103/jab.2024.24337.1627>
- Mohammadabadi, M., Golkar, A., & Askari Hesni, M. (2023). The effect of fennel (*Foeniculum vulgare*) on insulin-like growth factor 1 gene expression in the rumen tissue of Kermani sheep. *Agricultural Biotechnology Journal*, 15(4), 239–256. <https://doi.org/10.22103/jab.2023.22647.1530>
- Mohammadabadi, M., Shaban Jorjandy, D., Arabpoor Raghavadi, Z., Abareghi, F., Sasan, H. A., & Bordbar, F. (2022). The role of fennel on DLK1 gene expression in sheep heart tissue. *Agricultural Biotechnology Journal*, 14(2), 155–170. <https://doi.org/10.22103/jab.2022.19402.1399>
- Najafi, N. N., Armide, N., Akbari, A., Rahimi, V. B., & Askari, V. R. (2024). Quercetin a promising functional food additive against allergic diseases: A comprehensive and mechanistic review. *Journal of Functional Foods*, 116, Article 106152. <https://doi.org/10.1016/j.jff.2024.106152>

- Oliveira, T. T., Campos, K. M., Cerqueira-Lima, A. T., Cana Brasil Carneiro, T., da Silva Velozo, E., Ribeiro Melo, I. C., Figueiredo, E. A., de Jesus Oliveira, E., de Vasconcelos, D. F., Pontes-de-Carvalho, L. C., Alcântara-Neves, N. M., & Figueiredo, C. A. (2015). Potential therapeutic effect of *Allium cepa* L. and quercetin in a murine model of *Blomia tropicalis* induced asthma. *DARU Journal of Pharmaceutical Sciences*, *23*, Article 18. <https://doi.org/10.1186/s40199-015-0098-5>
- Ounaceur, L. S., Messarah, M., Lankar, A., Touaibia, D., Ghadab, H., Garri, Z., Boudjil, S., Belkacem Djefjel, K., Atoui, L., Ounaceur, A., Djaber, N., & Boumendjel, A. (2024). In vivo determination of the anti-inflammatory and antioxidant effects of the aqueous extract of *Syzygium aromaticum* (clove) in an asthmatic rat model. *Cellular and Molecular Biology*, *70*(3), 29–39. <https://doi.org/10.14715/cmb/2024.70.3.5>
- Pan, C., & Dong, Z. (2015). Antiasthmatic effects of eugenol in a mouse model of allergic asthma by regulation of vitamin D3 upregulated protein 1/NF-κB pathway. *Inflammation*, *38*(4), 1385–1393. <https://doi.org/10.1007/s10753-015-0110-8>
- Pandey, A., Vishnoi, K., Mahata, S., Tripathi, S. C., Misra, S. P., Misra, V., Mehrotra, R., Dwivedi, M., & Bharti, A. C. (2015). Berberine and curcumin target survivin and STAT3 in gastric cancer cells and synergize actions of standard chemotherapeutic 5-fluorouracil. *Nutrition and Cancer*, *67*(8), 1293–1304. <https://doi.org/10.1080/01635581.2015.1085581>
- Rogério, A. P., Dora, C. L., Andrade, E. L., Chaves, J. S., Silva, L. F., Lemos-Senna, E., & Calixto, J. B. (2010). Anti-inflammatory effect of quercetin-loaded microemulsion in the airways allergic inflammatory model in mice. *Pharmacological Research*, *61*(4), 288–297. <https://doi.org/10.1016/j.phrs.2009.10.005>
- Safaei, S. M. H., Dadpasand, M., Mohammadabadi, M., Atashi, H., Stavetska, R., Klopenko, N., & Kalashnyk, O. (2022). An *Origanum majorana* leaf diet influences myogenin gene expression, performance, and carcass characteristics in lambs. *Animals*, *13*(1), Article 14. <https://doi.org/10.3390/ani13010014>
- SAS Institute. (2018). *Statistical Analysis System user's guide* (Version 9.6). SAS Institute.
- Shahsavari, M., Mohammadabadi, M., Khezri, A., Afanasenko, V., & Kondratiuk, V. (2022). Effect of fennel (*Foeniculum vulgare*) seed powder consumption on insulin-like growth factor 1 gene expression in the liver tissue of growing lambs. *Gene Expression*, *21*(2), 21–26. <https://doi.org/10.14218/GE.2022.00017>
- Shahsavari, M., Mohammadabadi, M., Khezri, A., Asadi Fozi, M., Babenko, O., Kalashnyk, O., Oleshko, V., & Tkachenko, S. (2023). Correlation between insulin-like growth factor 1 gene expression and fennel (*Foeniculum vulgare*) seed powder consumption in muscle of

- sheep. *Animal Biotechnology*, 34(4), 882–892.  
<https://doi.org/10.1080/10495398.2021.2000997>
- Shokri, S., Khezri, A., Mohammadabadi, M., & Kheyrodin, H. (2023). The expression of MYH7 gene in femur, humeral muscle, and back muscle tissues of fattening lambs of the Kermani breed. *Agricultural Biotechnology Journal*, 15(2), 217–236.  
<https://doi.org/10.22103/jab.2023.21524.1486>
- Srivastava, N. S., & Srivastava, R. A. K. (2019). Curcumin and quercetin synergistically inhibit cancer cell proliferation in multiple cancer cells and modulate Wnt/ $\beta$ -catenin signaling and apoptotic pathways in A375 cells. *Phytomedicine*, 52, 117–128.  
<https://doi.org/10.1016/j.phymed.2018.09.224>
- Temelkovski, J., Hogan, S. P., Shepherd, D. P., Foster, P. S., & Kumar, R. K. (1998). An improved murine model of asthma: Selective airway inflammation, epithelial lesions and increased methacholine responsiveness following chronic exposure to aerosolised allergen. *Thorax*, 53(10), 849–856. <https://doi.org/10.1136/thx.53.10.849>
- Vahabzadeh, M., Chamani, M., Dayani, O., & Sadeghi, A. A. (2020). Effect of *Origanum majorana* leaf (sweet marjoram) feeding on lamb's growth, carcass characteristics, and blood biochemical parameters. *Small Ruminant Research*, 192, Article 106233.  
<https://doi.org/10.1016/j.smallrumres.2020.106233>
- Xu, D., Wan, C., Wang, T., Tian, P., Li, D., Wu, Y., Fan, S., Chen, L., Shen, Y., & Wen, F. (2015). Berberine attenuates cigarette smoke-induced airway inflammation and mucus hypersecretion in mice. *International Journal of Clinical and Experimental Medicine*, 8(6), 8641–8647. <https://pmc.ncbi.nlm.nih.gov/articles/PMC4538094/>

## تأثیر کمپلکس Quercetin Berberine و عصاره میخک بر وضعیت آسم القا شده در موش‌ها

رؤی ج. محمد 

نویسنده مسئول: بخش میکروبیولوژی، دانشکده دامپزشکی، دانشگاه بغداد، استان بغداد، عراق. پست الکترونیک:

ruaa.jassem1103a@covm.uobaghdad.edu.iq

تاریخ دریافت: ۱۴۰۴/۰۳/۱۲ تاریخ دریافت فایل اصلاح شده نهایی: ۱۴۰۴/۰۶/۰۳ تاریخ پذیرش: ۱۴۰۴/۰۶/۰۴

### چکیده

**هدف:** آسم یک اختلال التهابی مزمن مجاری هوایی است که با بیش‌واکنشی و تغییرات ساختاری شناخته می‌شود و عمدتاً ناشی از بی‌نظمی ایمنی است. ترکیبات طبیعی مانند بربرین، کوئرستین و عصاره میخک دارای ویژگی‌های ضدالتهابی و آنتی‌اکسیدانی هستند. این پژوهش با هدف بررسی واکنش‌های ایمنی‌تعدیل‌گر و حفاظتی ترکیب کوئرستین-بربرین و عصاره میخک در الگوی آسم القاشده با اوالبومین (OVA) در موش‌ها انجام شد.

**مواد و روش‌ها:** سی موش سوییس از هر دو جنس به‌صورت تصادفی به سه گروه (۱۰ موش در هر گروه) تقسیم شدند. گروه اول دوز خوراکی ترکیب کوئرستین-بربرین (۱۰۰ میلی‌گرم بر میلی‌لیتر، ۰/۱ میلی‌لیتر) را یک‌بار در هفته به‌مدت ۸ هفته دریافت کرد. گروه دوم با همان رژیم درمانی عصاره میخک دریافت نمود. گروه سوم به‌عنوان کنترل مثبت در روز اول و مجدداً پس از ۸ هفته ۱۰ درصد OVA (۰/۳ میلی‌لیتر، به‌صورت داخل صفاقی) برای القای آسم دریافت کرد. در پایان دوره درمان، نمونه‌های خون و سرم جهت سنجش شمارش گلبول‌های سفید (WBC)، ایمونوگلوبولین E (IgE) و اینترلوکین-۴ (IL-4) به روش ELISA جمع‌آوری شد. سپس تمام گروه‌های آزمایشی پیش از euthanasia در هفته نهم مجدداً با OVA (۰/۳ میلی‌لیتر، داخل صفاقی) تیمار شدند. در ادامه بررسی آسیب‌شناسی بافتی ریه و نای انجام گرفت.

**نتایج:** درمان با ترکیب کوئرستین-بربرین یا عصاره میخک موجب کاهش معنادار شمارش WBC، سطح IL-4 و IgE در مقایسه با گروه کنترل مثبت گردید ( $p \leq 0.05$ ). تحلیل آسیب‌شناسی بافتی کاهش چشمگیری در التهاب راه‌های هوایی، نفوذ سلولی و تخریب بافتی در گروه‌های درمانی نشان داد که بیانگر کاهش پاتولوژی ریوی ناشی از OVA بود. هر دو درمان واکنش‌های حفاظتی مشابهی بروز دادند و شواهدی از بازسازی یکپارچگی بافتی در مقایسه با گروه‌های درمان‌نشده مشاهده شد.

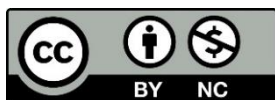**نتیجه‌گیری:** نتایج نشان می‌دهد که ترکیب کوئرستین-بربرین و عصاره میخک فعالیت ایمنی تعدیل‌گر قوی داشته و پاسخ‌های التهابی و تخریب بافتی در آسم القاشده با OVA را کاهش می‌دهند. این یافته‌ها پتانسیل درمانی ترکیبات گیاهی را به‌عنوان راهکارهای کمکی یا جایگزین در مدیریت التهاب مجاری هوایی و آسم برجسته می‌سازند. برای روشن شدن سازوکارهای مولکولی زمینه‌ای و بررسی اهمیت بالینی آن‌ها تحقیقات بیشتری لازم است.

**کلمات کلیدی:** آسم، اووالبومین، تعدیل ایمنی، عصاره میخک، ELISA

**نوع مقاله:** پژوهشی.

**استناد:** رؤی ج. محمد (۱۴۰۴). تأثیر کمپلکس Quercetin Berberine و عصاره میخک بر وضعیت آسم القا شده در موش‌ها. *مجله بیوتکنولوژی کشاورزی*، ۱۷(۳)، ۴۰۱-۴۲۲.

Publisher: Shahid Bahonar University of Kerman & Iranian



Biotechnology Society.

© the authors