



Investigating the cardioprotective effects of *Illicium verum* Against doxorubicin-induced cardiotoxicity in rats

Haitham L. Abdulhadi 

Department of Biology, College of Education for Pure Sciences, University of Anbar, Ramadi, Anbar 31001, Iraq. E-mail: haytham.lateif@uoanbar.edu.iq

Abstract

Objective

One of the chemotherapy drugs used to treat many cancers in the world is doxorubicin (DOX). However, this drug cannot be used indefinitely for treatment. Because it can cause dose-dependent cardiotoxicity. This toxicity causes inflammation and damage to cardiac tissue and oxidative stress. Therefore, the aim of our study was to investigate the potential cardioprotective effects of *Illicium verum* extract against DOX-induced cardiotoxicity in rats.

Materials and methods

Four groups of mice that were randomly selected were used in this experiment. These four groups included the control group, the DOX-treated group, the 100 mg/kg *Illicium verum* extract treatment group, and the 200 mg/kg *Illicium verum* extract treatment group. The extract was administered orally for 7 days. Then, DOX injection was performed. The extract was administered orally for 7 days after the injection. Serum cardiac biomarkers including cardiac troponin-I (cTn-I), creatine kinase-MB (CK-MB), and lactate dehydrogenase (LDH) were measured to assess cardiac injury. To complete the evaluations, we also measured inflammatory cytokines (IL-6 and TNF- α), oxidative stress markers (malondialdehyde (MDA) and myeloperoxidase (MPO)), and antioxidant parameters (glutathione (GSH) and nitric oxide (NO)). To assess structural damage to cardiac tissue, we also performed histopathological studies.

Results

DOX injection resulted in significant increases in cardiac enzymes, inflammatory cytokines, and oxidative stress markers and decreased antioxidant levels. These indicate its cardiotoxic effect. Treatment with *Illicium verum* extract before injection improved the aforementioned biochemical parameters in a dose-dependent manner. The highest protective effect was observed in the 200 mg/kg extract group. This treatment had lower levels of cardiac injury markers and inflammatory mediators compared to the DOX group. In the extract-treated groups, myocardial injury was reduced, cellular degeneration was reduced, and tissue structure was improved.

Conclusion

Based on the results of this study, it can be suggested that *Illicium verum* extract can have significant cardioprotective effects against DOX-induced cardiotoxicity. These positive effects

may be due to its antioxidant and anti-inflammatory properties. Therefore, it is hoped that *Illicium verum* can be used to reduce cardiac damage associated with doxorubicin treatment. However, further studies on a larger scale are needed to draw definitive conclusions.

Keywords: cardiac biomarkers, cardiotoxicity, *Illicium verum*, inflammation, oxidative stress

Paper Type: Research Paper.

Citation: Abdulhadi, H. L. (2026). Investigating the cardioprotective effects of *Illicium verum* Against doxorubicin-induced cardiotoxicity in rats. *Agricultural Biotechnology Journal*, 18(3), 155-176.

Agricultural Biotechnology Journal, 18(3), 155-176. DOI: 10.22103/jab.2026.26830.1851

Received: January 10, 2026.

Received in revised form: March 06, 2026.

Accepted: March 07, 2026.

Published online: June 30, 2026.

Publisher: Shahid Bahonar University of Kerman & Iranian

Biotechnology Society.

© the authors



Introduction

Doxorubicin (DOX) is a popular and effective antitumor drug against multiple cancers that include breast cancer, sarcomas, lymphomas and leukemias (Rawat *et al.*, 2021). Nevertheless, its application is restricted by dose-dependent cardiotoxicity and related heart failure, which may persist several years after the use (Linders *et al.*, 2024). Cardiotoxicity is due to a predominant apoptosis pathway involving oxidative stress, mitochondrial and lysosomal dysfunction, and inflammation (Lin *et al.*, 2023). Reactive oxygen species (ROS) generated by DOX disrupt the redox balance and alter intracellular calcium homeostasis, leading to cardiomyocyte apoptosis (Sies *et al.*, 2022). Mitochondria are prime targets of DOX cardiotoxicity, generation of superoxide, hydroxyl radicals, or peroxynitrite from impaired xanthine oxidase, increased NO synthase activity, or decreased melatonergic defenses have been reported (Eisvand *et al.*, 2022). Doxorubicin rapidly induces the production of ROS and NO and oxidative damage to DNA in the heart (Wu *et al.*, 2023). In addition, lipoperoxidation was reported after DOX treatment in rat cardiomyocytes. DOX-induced oxidative and nitrative stress results in mitochondrial dysfunction and cardiomyocyte apoptosis (Syahputra *et al.*, 2022). Despite the clinical success of DOX, it is well recognized that its administration can cause acute toxicity expressed by aggravation of the arrhythmias, peripheral vascular spasms, and vasculitis of the skin (Bhutani *et al.*, 2025). Sudden death and myocardial injury may be due to the depolarization of myocardial tissue or dysrhythmia caused by the disruption of the cardiac action potential increase in the renewable emissions of free radicals (Ali and Alkarbolii, 2024). Several agents such as lipid-lowering drugs, hormones, vitamins, and natural extracts have been examined for potential cardioprotection against DOX-induced toxicity (Chaulin, 2023). Moreover, Phytobiotics and medicinal plants have gained considerable attention in recent years due to their potential as natural alternatives to synthetic

additives in nutrition. These natural products are rich in bioactive compounds such as essential oils, alkaloids, flavonoids, and phenolic acids, which contribute to their antimicrobial, antioxidant, anticancer, and anti-inflammatory properties. Consequently, phytobiotics play a crucial role in improving health, performance, and immunity. The use of phytobiotics and medicinal plants as natural antimicrobial growth promoters in place of antibiotics in feed offers numerous advantages. These benefits include improved zootechnical efficiency parameters, suppression of specific diseases (Mohammadabadi et al., 2023), antimicrobial and antioxidant activities, hypocholesterolemic effects, enhancement of digestive enzymes, anticancer role, and improved liver function. Moreover, phytobiotics have been shown to modulate gut microbiota, which enhances nutrient absorption and supports overall immune function (Vahabzadeh et al., 2021). Studies have demonstrated that incorporating these plants into the diets can increase feed consumption, improve feed conversion to muscle, and enhance physical ability. Furthermore, phytobiotics are associated with reducing stress-related impacts, improving meat quality, regulating gene expression involved in cancer, and decreasing the environmental impact of animal production systems by optimizing nutrient utilization (Mohammadabadi et al., 2024). *Illicium verum*, commonly known as star anise, is an evergreen tree or shrub of the family Illiciaceae (Sharafan et al., 2022). It is native to northeast Indochina, southern China, the Philippines, Taiwan and Japan (Yang et al., 2021). *Illicium verum* is widely distributed in tropical and warm temperate regions, grown for the commercial spice that consists of fruit, bark, and leaf. *Illicium verum* is a spice utilized worldwide for its distinctive flavor. Besides flavoring food, *Illicium verum* has several medicinal properties, such as smooth muscle relaxant, anti-inflammatory, anti-tumor, and cardioprotective agents against isoproterenol-induced cardiotoxicity (Singh and Verma, 2024). Preliminary phytochemical screening of the active hexane fraction of *Illicium verum* leaves revealed the presence of phenolic compounds, flavonoids, terpenoids, and saponins, which may be responsible for its inflammation-modulating activity (Karim et al., 2023). Despite the cardioprotective potential of *Illicium verum*, its risk-benefit ratio in the context of cardiotoxicity has not been investigated. This experiment was designed to determine the effectiveness of star anise on some histological and biochemical variables of the heart muscle in rats exposed to doxorubicin.

Materials and methods

Animal model-Selection and housing: The ethical permission of this study was obtained from the Institutional Animal Care and Use Committee (IACUC) of University of Anbar. Forty male Wistar rats weighing 200–220 g were obtained from biology department of Collage of education for pure sciences in university of Anbar. The animals were housed in clean standard cages under controlled room temperature ($25\pm 2^{\circ}\text{C}$) and light-dark cycle (12:12 hours) and provided with standard chow diet and water ad libitum. The animals were treated humanely throughout the experiments. The animals were acclimatized to the laboratory conditions and the experimental protocols for 1 week.

Preparation of *Illicium Verum* extract: The heart of exactly 9 Wistar rats (140-250 g, 5 weeks old) was used as a sample. Water was selected as a suitable solvent due to its hydrophilic nature. The fresh *Illicium verum* fruit was cleaned, dried, and chopped with a mechanical grinder. The dried fruit (30 g) was boiled with 300 ml of water for 30 minutes. The solution was filtered through double layered cheese cloths to get the cold extract. The crude extract was then concentrated using a laboratory freeze dryer and stored at 2-4 °C, or in an ultra-low-temperature laboratory freezer (-40 °C). The yield percentage was 70%. Stock solution of *I. verum* was prepared by dissolving 100 mg of freeze-dried crude power in 100 ml of distilled water. The final working concentrations (100 and 200 mg/kg) were prepared by diluting the stock solution (Yang *et al.*, 2021).

Experimental design: Following a week of habituation, the animals were randomly assigned to four groups (ten animals in each group) a day before the experimentation. Group one was retained as the normal control. Group two was given doxorubicin to induce cardiotoxicity (5 mg/2mL) was used as an aqueous solution and was administered intravenously (2.5 mg/kg, 0.5 mL) via the tail vein. Groups three was received Fresh extracts of *Illicium verum* in drinking water at the doses of 100 mg/kg, group four were given Fresh extracts of *Illicium verum* in drinking water at the doses of 200 mg/kg. Groups three and four were administered 7 days prior to administration of doxorubicin and continued for 7 days post doxorubicin.

Sample collection and tissue preparation: At the end of the experimental period, animals were anesthetized, and blood samples were collected directly from the heart using a sterile syringe. The blood was left to clot at room temperature and centrifuged at 3000 rpm over a period of 15 minutes in order to obtain the serum, which was kept at -20o C to further undergo biochemical and immunological tests. After the blood was drawn the hearts were immediately removed, washed in cold saline and carried out to the histological lab.

Biochemical and immunological assessments- The cardiac Troponin-I (cTn-I) measurement: An enzyme-linked immunosorbent assay (ELISA) kit of cardiac troponin-I (cTn-I) in serum was used to determine the level of the enzyme using the instructions of the manufacturer (Elabscience, USA). Wells were pre coated with serum samples and incubated with specific antibodies. Washing and reaction with substrate was followed by reading of the absorbance at 450 nm with the help of microplate reader (BioTek Instruments, USA).

Creatine Kinase-MB (CK-MB) activity: The CK-MB level was measured spectrophotometrically, with the help of a diagnostic kit (BioSystems S.A., Barcelona, Spain). The principle is on the enzymatic transformation of creatine phosphate to creatine with the resultant generation of NADPH, which is detected at 340 nm. The levels were given in U/L.

Lactate dehydrogenase (LDH) activity: LDH activity in serum was assessed using a colorimetric method with a commercially available kit (Randox Laboratories, UK). The reaction is based on the reduction of pyruvate to lactate with simultaneous oxidation of NADH to NAD⁺, and the decrease in absorbance at 340 nm was monitored. Results were expressed in U/L.

Nitric oxide (NO) levels: Serum nitric oxide levels were estimated indirectly by measuring the stable end products nitrite and nitrate using the Griess reagent method. A standard curve was

prepared using sodium nitrite, and absorbance was read at 540 nm using a spectrophotometer (Archer, 1993).

Myeloperoxidase (MPO) activity: MPO activity was determined using an ELISA kit (Abcam, UK) following the manufacturer's protocol. Briefly, samples were incubated in microtiter plates coated with MPO-specific antibodies, followed by reaction with chromogenic substrates, and absorbance was measured at 450 nm.

Interleukin-6 (IL-6) and tumor necrosis factor- α (TNF- α): Levels of IL-6 and TNF- α were quantified using sandwich ELISA kits (Thermo Fisher Scientific, USA). Standards and samples were loaded onto wells pre-coated with specific capture antibodies. After a series of binding and washing steps, detection antibodies and substrate were added. The intensity of the color reaction was measured at 450 nm, and concentrations were calculated based on the standard curve.

Malondialdehyde (MDA) measurement: MDA levels, as a marker of lipid peroxidation, were determined using the thiobarbituric acid reactive substances (TBARS) assay. Thiobarbituric acid (TBA) and trichloroacetic acid (TCA) were added to serum samples, and boiled in a water bath at 100 o C. Supernatant was cooled, centrifuged and absorbance of the supernatant measured at 532 nm.

Reduced glutathione (GSH) measurement: The concentration of GSH was analyzed by Ellman reagent (5, 5' dithiobis 2- nitro benzoic acid) DTNB. Sulfosalicylic acid was used to deproteinize the serum prior to the mixture of serum using phosphate buffer and DTNB solution. At 412 nm, the spectrophotometer was used to measure the intensity of the yellow color (Hissin and Hilf, 1976).

Histological preparation: The cardiac tissues were preserved in 10% neutral buffered formalin 24 hours and dehydrated with graded ethanol, cleared with xylene and embedded in paraffin. Thick sections (5 mm) were sectioned, placed on slides, deparaffinized, and stained with hematoxylin and eosin. Lastly, the stained areas were dried, debrided and studied under a light microscope to analyze the histological details (Bancroft and Gamble, 2008).

Results

Under the experimental procedure, all animals were able to tolerate the treatments with no deaths or clear negative effects. The biochemical and immunological analyses showed that there were substantial changes caused by doxorubicin (DOX) and the modulative impact of *Illicium verum* extracts.

Cardiac biomarkers: A significant increase in the serum cardiac troponin-I (cTn-I), creatine kinase-MB (CK-MB), and lactate dehydrogenase (LDH) activities was observed in the administration of DOX over normal control condition ($p < 0.05$). These levels indicate myocardial damage and heart failure caused by DOX. The *Illicium verum* extract 100 mg/kg and 200 mg/kg pretreatment caused significant reduction of these cardiac enzymes in comparison with the DOX-only group ($p < 0.05$). The decrease was dose dependent where the high dose (200 mg/kg) exhibited higher cardioprotective effect and the value was nearer to that of the normal control (Figures 1, 2 and 3).

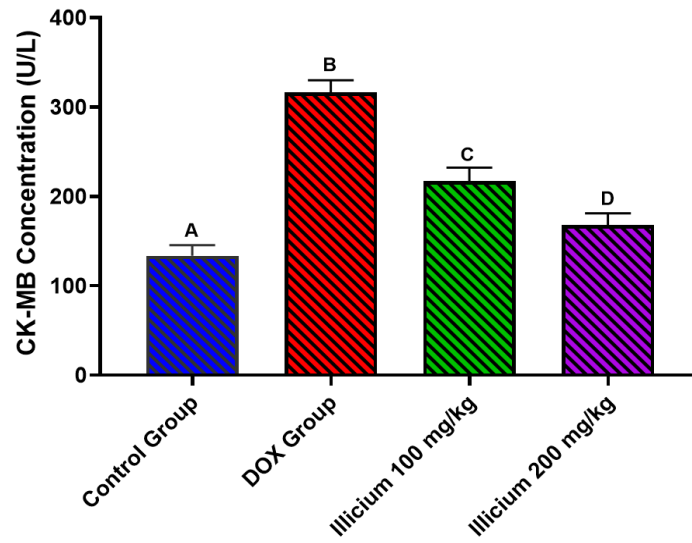


Figure 1. The effect of *Illicium verum* extract on the level of some cardiac enzymes in rats treated with doxorubicin. Different capital letters indicate significant differences between the different groups, while similar letters indicate no significant differences

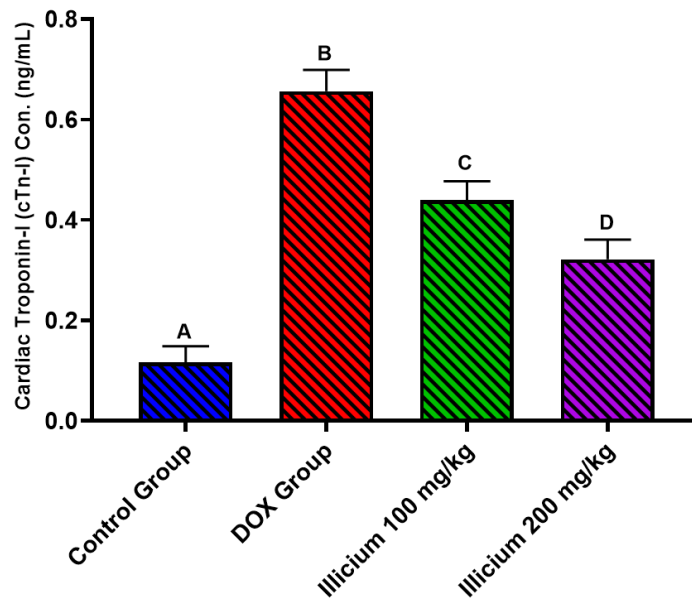


Figure 2 The effect of *Illicium verum* extract on the level of some cardiac enzymes in rats treated with doxorubicin. Different capital letters indicate significant differences between the different groups, while similar letters indicate no significant differences

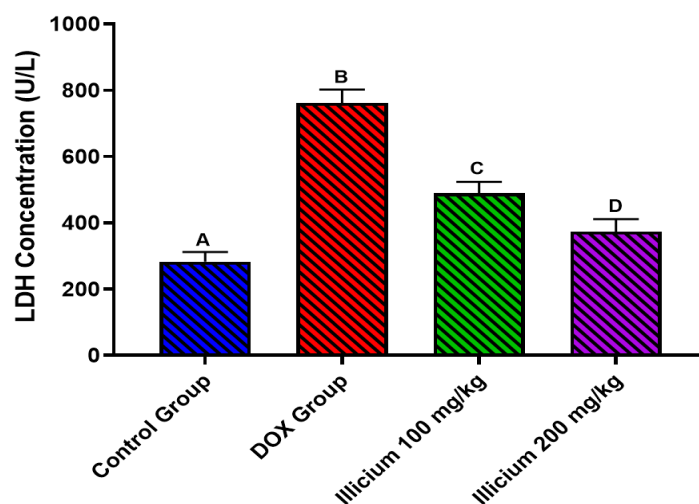


Figure 3. The effect of *Illicium verum* extract on the level of some cardiac enzymes in rats treated with doxorubicin. Different capital letters indicate significant differences between the different groups, while similar letters indicate no significant differences

Inflammatory markers: Doxorubicin administration significantly elevated pro-inflammatory cytokines, including interleukin-6 (IL-6) and tumor necrosis factor-alpha (TNF- α), relative to the control group ($p < 0.05$), indicating an inflammatory response associated with cardiac injury. Both doses of *Illicium verum* extract significantly suppressed the elevation of IL-6 and TNF- α compared to the DOX group ($p < 0.05$). This suggests that the extract exerts an anti-inflammatory effect that may contribute to its protective properties against DOX-induced cardiotoxicity (Figures 4, 5).

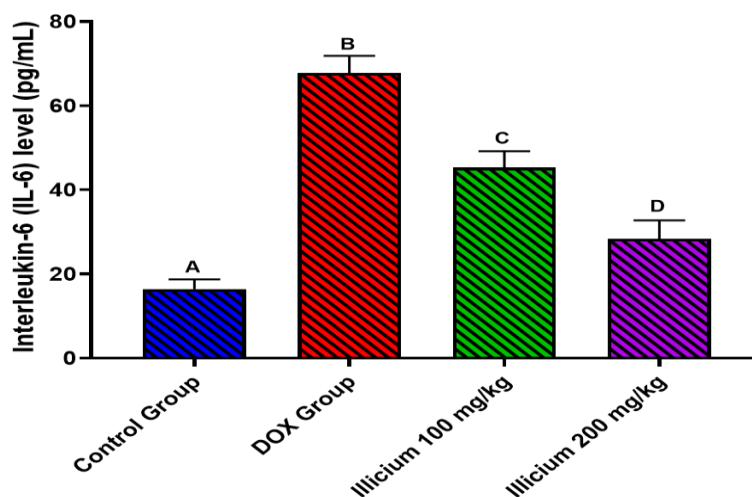


Figure 4. The effect of *Illicium verum* extract on the level of some inflammatory mediators in rats treated with doxorubicin. Different capital letters indicate significant differences between the different groups, while similar letters indicate no significant differences

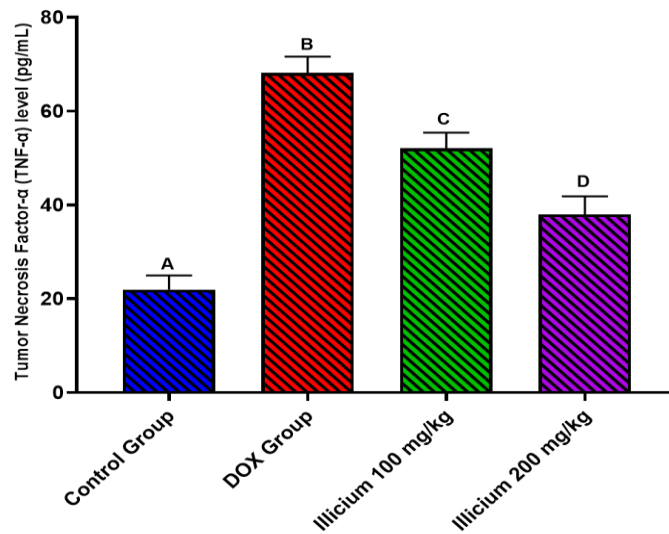


Figure 5. The effect of *Illicium verum* extract on the level of some inflammatory mediators in rats treated with doxorubicin. Different capital letters indicate significant differences between the different groups, while similar letters indicate no significant differences

Oxidative stress and antioxidant parameters: Oxidative stress biomarkers were also significantly affected by DOX treatment (Figures 6, 7, 8, 9). There was a pronounced increase in malondialdehyde (MDA) levels, a marker of lipid peroxidation, and myeloperoxidase (MPO) activity, reflecting enhanced oxidative and neutrophil-mediated inflammatory damage ($p < 0.05$ versus control). On the other hand, the endogenous antioxidant levels lowered the glutathione (GSH) and nitric oxide (NO) in the DOX group ($p < 0.05$), which means that the antioxidant defense mechanisms were damaged.

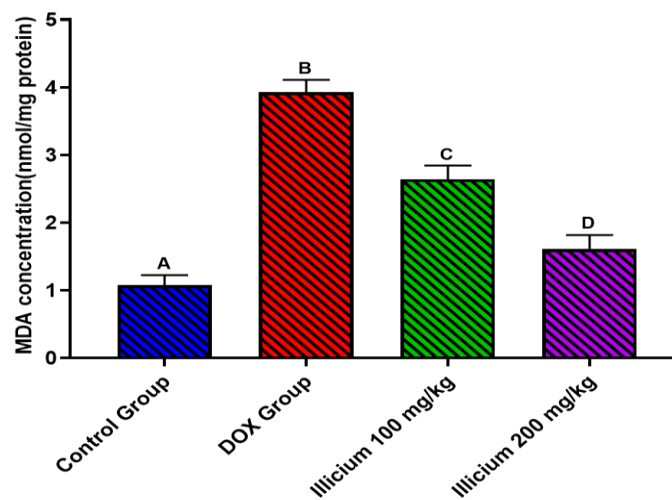


Figure 6. The effect of *Illicium verum* extract on the level of MDA in rats treated with doxorubicin. Different capital letters indicate significant differences between the different groups, while similar letters indicate no significant differences

Illicium verum extract treatment at both dose levels provided significant mitigatory effects on such oxidative disturbances by reducing the levels of MDA and MPO and by recovering the levels of GSH and NO to the normal values ($p < 0.05$). The ameliorations were more noticeable with the 200mg/kg dose.

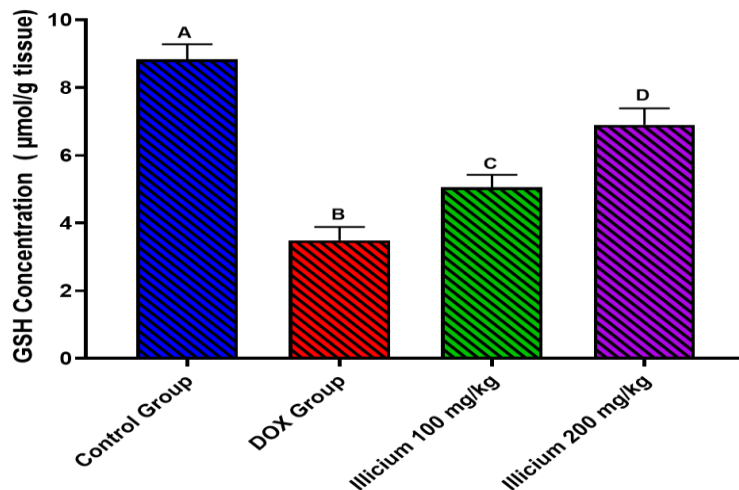


Figure 7. The effect of *Illicium verum* extract on the level of GSH in rats treated with doxorubicin. Different capital letters indicate significant differences between the different groups, while similar letters indicate no significant differences

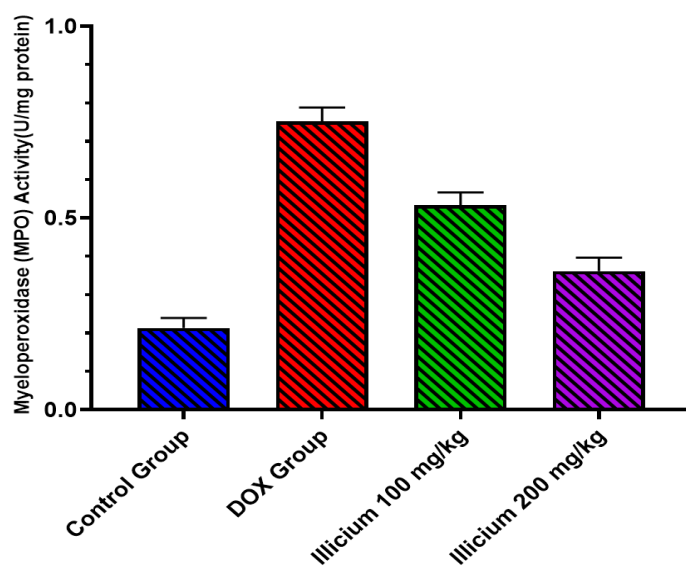


Figure 8. The effect of *Illicium verum* extract on the level of MPO in rats treated with doxorubicin. Different capital letters indicate significant differences between the different groups, while similar letters indicate no significant differences

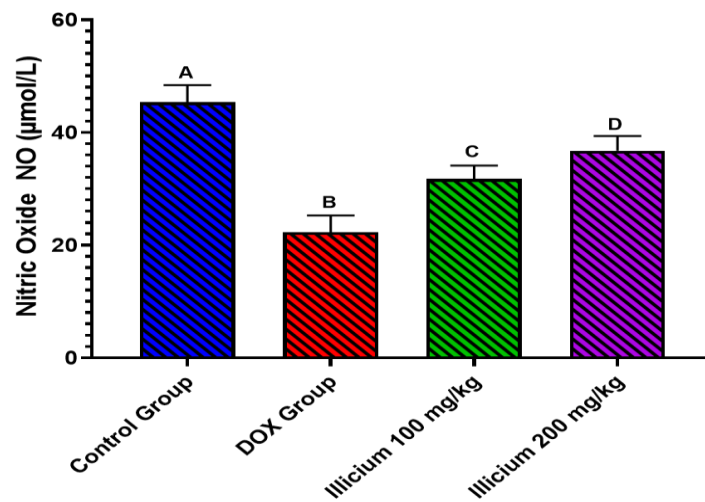


Figure 9. The effect of *Illicium verum* extract on the level of Nitric oxide in rats treated with doxorubicin. Different capital letters indicate significant differences between the different groups, while similar letters indicate no significant differences

Histopathological results: The sections of the cardiac tissues-stained hematoxylin and eosin and viewed under light microscope indicated that there were morphological differences between the experimental groups. The control group whose myocardium was exposed to the external environment had a normal integrity of the myocardial structure, with regularly arranged myofibrils (MF) and oval-shaped elongated nuclei (EN) of the cardiomyocytes, without inflammatory or degenerative forms (Figure 10). On the other hand, the treated group of doxorubicin showed severe structural disorganization, characterized by general disintegration of myofibrils, gross vascular congestions (CON), intense inflammatory infiltrates (IL) as well as cellular degeneration (D). These alterations implied the presence of large amounts of myocardial injury that had been caused by the cardiotoxic effect of doxorubicin (Figures 11, 12). Partial structural maintenance of the myocardium was confirmed in the group to which *Illicium verum* extract of dose level 100 mg/kg was administered. The heart fibers were moderately arranged as it was observed that they contained elongated nuclei, but there were observable decreases of cellular degeneration and interstitial hemorrhage (HE) indicating that the protective effect has not been complete at this dose (Figures 13, 14). Significant change was observed in the histological aspect in those who were treated with *Illicium verum* extract in higher dose of 200 mg/kg of the compound. The myofibrils had been arranged and were mostly preserved, nuclei were still elongated and homogenous, and the presence of inflammation was minimal. There was no evidence to show any major hemorrhage or necrosis that was present in this group and this implies that the myocardial damage was largely reduced (Figure 15).

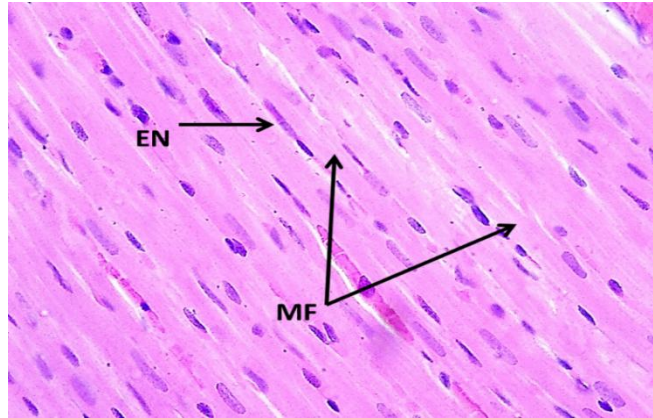


Figure 10. A cross section of the myocardium in control group showing the normal histological structure of cardiac myofibrils (MF), elongated oval nuclei (EN)

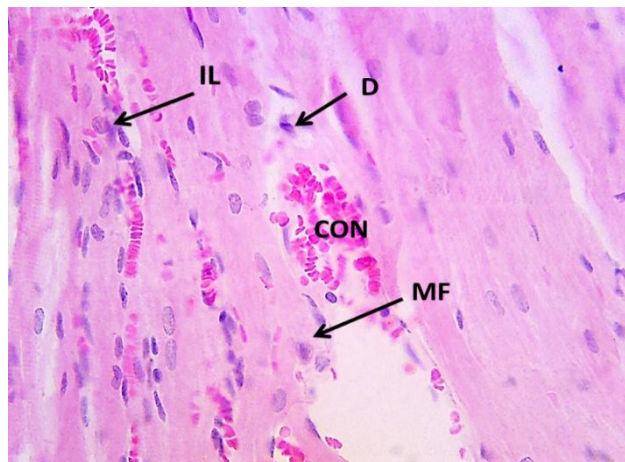


Figure 11. Cross section of the myocardium of the doxorubicin group showing irregularity and disintegration of myofibrils (MF), severe congestion (CON), inflammatory infiltrate (IL), and cellular degeneration(D)

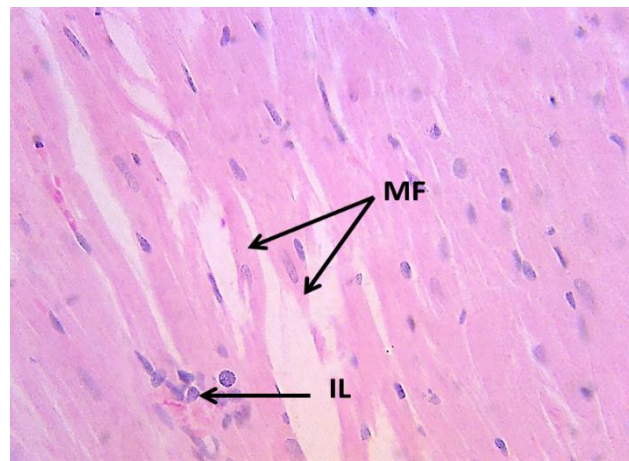


Figure 12. Cross section of myocardium of Doxorubicin group showing disintegration of myofibrils (MF), inflammatory infiltrate (IL)

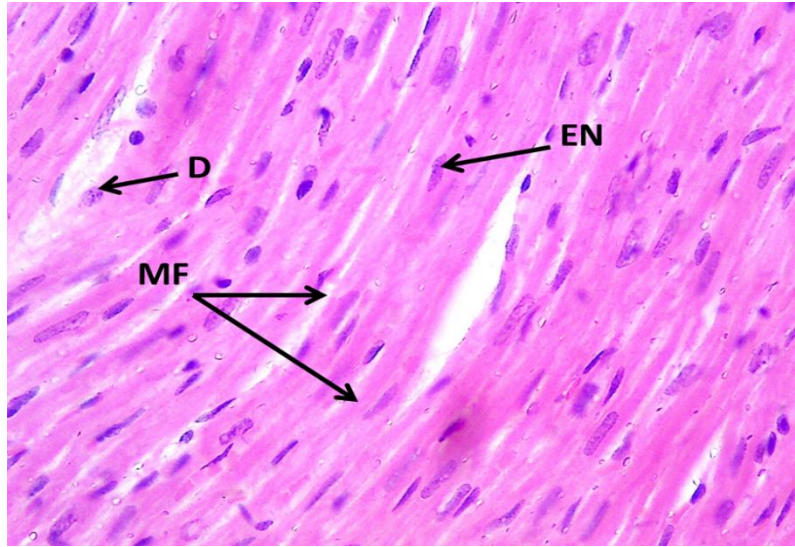


Figure 13. Cross section of the myocardium in the treatment group (100 mg/kg *Illicium verum* extracts) showing myofibrils (MF), elongated oval nuclei (EN), and cell degeneration (D)

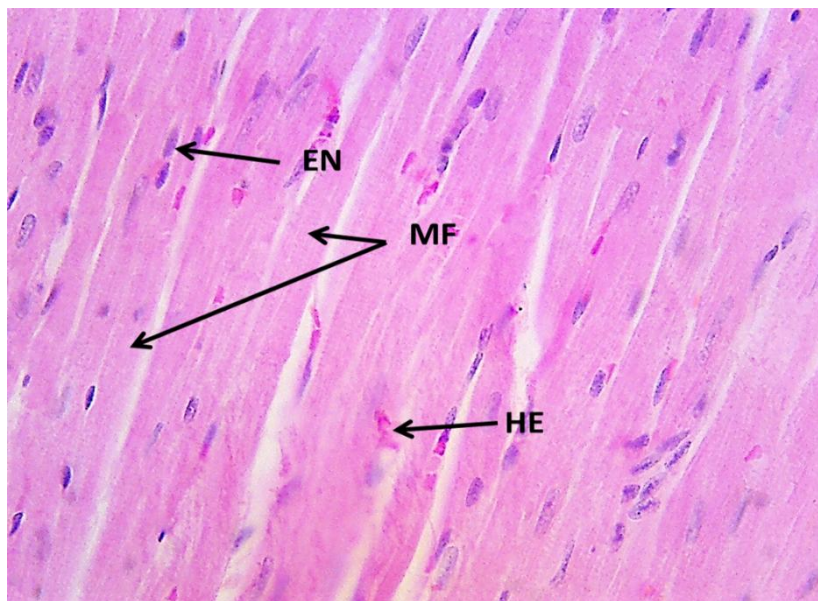


Figure 14. Cross section of the myocardium in the treatment group (100 mg/kg *Illicium verum* extracts) showing myofibrils (MF), elongated oval nuclei (EN), and hemorrhage (HE)

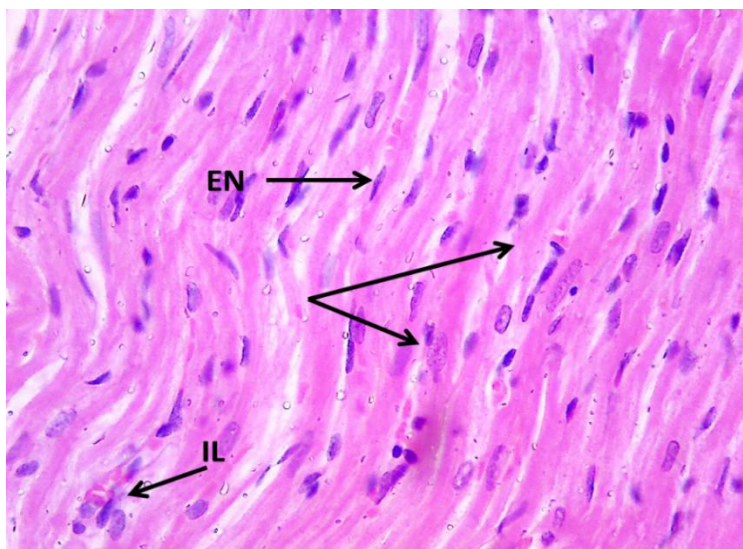


Figure 15. Cross section of the myocardium in the treatment group (200 mg/kg *Illicium verum* extracts) showing myofibrils (MF), elongated oval nuclei (EN), and inflammatory infiltrate (HE)

Discussion

Based on the results of the present research, it is quite obvious that the administration of doxorubicin led to serious cardiotoxic effects of the experimental animals which were reflected by the severe changes in various biochemical and inflammatory parameters. The described increase of the cardiac-specific parameters such as cardiac troponin-I, creatine kinase-MB, and lactate dehydrogenase is a sign of massive myocardial damage (Cheah *et al.*, 2023). The reason behind this is most probably that the oxidative injury in this case is direct to the cardiomyocytes thus resulting in elevated permeability of the membrane and the seepage of the intracellular enzymes into the blood (Avagimyan *et al.*, 2024). In particular, troponin-I is a specific and extremely sensitive indicator of myocardial cell injury and its marked increase is based on acute cardiomyocyte necrosis. The increment of CK-MB and LDH is also attributed to the disruption of the cellular membrane and leakage of the cytoplasm due to the oxidative stress and alteration of the mitochondrial functions by doxorubicin (Naderi *et al.*, 2023). The doxorubicin group also showed high pro-inflammatory cytokines (interleukin-6 and tumor necrosis factor-alpha) in addition to biochemical evidence of cardiac damage. The cytokines are familiar agents of inflammatory cascade participating in cardiac remodeling and additional functional impairment (Cengiz *et al.*, 2021). TNF- α upregulation is able to cause cardiomyocyte apoptosis and deteriorate cardiac contractility, and IL-6 could stimulate local and systemic inflammation, and these characteristics are confirmed as the behavior of doxorubicin cardiotoxicity (Abdulkareem Aljumaily *et al.*, 2021). This means that the activated myeloperoxidase activity in this group is indicative of the neutrophil infiltration and stimulation which not only exaggerates the inflammatory responses, but also results in the production of the reactive oxygen species, thus promoting magnitude of the oxidative tissue damage (Mohamed *et al.*, 2022). There also was evidence of oxidative stress in the form of a marked elevation in malondialdehyde, an end result

of a lipid peroxidation product and a simultaneous reduction in the reduced glutathione and nitric oxide levels. These data support the hypothesis that oxidative imbalance plays an important role in cardiac injuries induced by doxorubicin (Yilmaz *et al.*, 2022). The decrease in the level of glutathione indicates its fast depletion in the course of neutralization of free radicals, whereas the loss of nitric oxide indicates endothelial dysfunction, which is usually accompanied by the occurrence of oxidative stress and loss of the vasodilator activity (Al-Amir *et al.*, 2023). In addition, reaction of nitric oxide with superoxide anions results in the generation of peroxynitrite, which is a highly cytotoxic molecule which worsens the injury caused to the cell (Yilmaz *et al.*, 2022). Interestingly, protection against these pathological changes was pronounced in terms of pretreatment with extract of *Illicium verum*. The extract resulted in a significant decrease in the amounts of cardiac biomarkers, which proves that it helps to maintain the integrity of myocardial cells (Khan *et al.*, 2022). Such effect was more evident in the higher dose of 200 mg/kg indicating a dose-dependent protective effect. The extract also reduced the level of IL-6, TNF- α and MPO by significant levels which is an indication of its strong anti-inflammatory effects (Majali, 2022). This anti-inflammation could take the path way of either inhibition of nuclear factor-kappa B signaling pathways or inhibition of pro-inflammatory gene expression, as indicated in previous phytochemical research (Mulla and Patil, 2025). Also, *Illicium verum* enhanced antioxidant levels by elevating the level of glutathione and nitric oxide and the level of malondialdehyde accumulation decreased. These findings can be used to verify the hypothesis that the extract increases endogenous antioxidant defence mechanisms and decreases the oxidative damage (Li *et al.*, 2022). These effects could be attributed to the presence of flavonoids, phenolic compounds and essential oils in *Illicium verum* that could directly scavenge free radicals or up regulate the antioxidant enzymes. The improvement of nitric oxide levels also implies some possible protection of endothelium, which could be a factor in improved microcirculation and decreased ischemic stress on the myocardium. Together, the evidence indicates that *Illicium verum* extract may be used as cardioprotective, and it possesses numerous effects of action, including oxidative stress alleviation, inflammatory inhibition, as well as preserving the structure of the heart cells (Zhu *et al.*, 2024). The remarkable strength of the dose 200mg/kg over the dose 100mg/kg encourages the action of concentration in providing therapeutic effects and warrants the need to conduct additional pharmacological research on an effective dose and the treatment period (Mohanasundari *et al.*, 2022). The findings of the histopathological analysis that follow in the current study would be to provide a clear indication of the damages that occur in the structure that have been catalyzed by doxorubicin and in protective role played by *Illicium verum* extract. The observed severe myofibril disintegration, inflammatory cell invasion and vessel congestions are all findings that are in line with the known mechanism of doxorubicin-induced cardiotoxicity that involves oxidative stress and mitochondrial dysfunction along with the release of inflammatory cytokines. These ones are the direct cytotoxic impact on cardiomyocytes and secondary damage performed with the help of reactive oxygen species and immune activation (Alhazzani *et al.*, 2021). The partial maintenance of myocardial architecture in the group assigned to the dosage of 100 mg/kg of *Illicium verum* indicates a medium protective effect on this portion. Even though the myofibril organization was better as compared to the doxorubicin group, the fact that cellular

degeneration and hemorrhage is evident is a pointer to the fact that the smaller dose was not enough to counter the pathological changes completely caused by doxorubicin (Iftikhar *et al.*, 2022). Conversely, the group that obtained 200 mg/kg of *Illicium verum* showed significant recovery of the myocardial structure. The almost unaltered histological expression which is seen in the well- preserved myofibrils, and little inflammatory alteration speaks of a strong protective action at this larger dose. This histological prevention falls in line with the biochemical results, which identified the 200 mg/kg dose to be related to a larger decrease in the cardiac enzymes, inflammatory cytokines and oxidative stress biomarkers (Iftikhar *et al.*, 2022). The cardiac architecture that is observed to be improved in this group can probably be credited to the antioxidative and anti-inflammatory characteristics of *Illicium verum* that can possibly reverse the injury mechanisms that have been set off by doxorubicin (Tuseef *et al.*, 2021). It is possible that the extract causes the stabilization of cell membranes, the lowering of oxidative damage, and prophylaxis of inflammatory cell infiltration, which is due to the presence of bioactive compounds in flavonoids, essential oils, and phenolics (Patra *et al.*, 2020). These histological results strengthen the possibility of *Illicium verum* working as cardioprotective agent especially at a stronger dose level, and to determine that the *Illicium verum* should be studied as an adjunctive remedy to reduce the heart damage caused by chemotherapy.

Conclusion: In conclusion, the present study provides compelling evidence that *Illicium verum* extract effectively ameliorates doxorubicin-induced cardiotoxicity by reducing oxidative stress and inflammatory responses. These findings support the therapeutic potential of *Illicium verum* as a natural cardioprotective agent during chemotherapy, warranting further mechanistic studies and clinical evaluation.

Author Contributions

Haitham L. Abdulhadi conceived and designed the study, conducted the experimental work, performed data collection and statistical analysis, interpreted the results, and wrote and revised the manuscript. The author has read and approved the final version of the manuscript.

Data Availability

The data supporting the findings of this study are available from the corresponding author upon reasonable request.

Acknowledgments

The author expresses sincere gratitude to the University of Anbar, Iraq, particularly the Department of Biology, College of Education for Pure Sciences, for providing laboratory facilities and technical support that made this research possible.

Ethical Considerations

All experimental procedures involving animals were conducted in accordance with the institutional guidelines for the care and use of laboratory animals. Ethical approval for this study

was obtained from the Institutional Animal Care and Use Committee (IACUC), University of Anbar, Iraq, under approval number 224, dated 4 March 2025.

Funding

This research is supported by the Department of Biology, College of Education for Pure Sciences, University of Anbar, Ramadi, Anbar, Iraq and this research received no external funding.

Conflict of Interest

The author declares that there are no conflicts of interest regarding the publication of this paper.

References

- Abdulkareem Aljumaily, S. A., Demir, M., Elbe, H., Yigitturk, G., Bicer, Y., & Altinoz, E. (2021). Antioxidant, anti-inflammatory, and anti-apoptotic effects of crocin against doxorubicin-induced myocardial toxicity in rats. *Environmental Science and Pollution Research*, 28(46), 65802–65813. <https://doi.org/10.1007/s11356-021-15409-w>
- Al-Amir, H., Janabi, A., & Hadi, N. R. (2023). Ameliorative effect of nebivolol in doxorubicin-induced cardiotoxicity. *Journal of Medicine and Life*, 16(9), 1357–1363. <https://doi.org/10.25122/jml-2023-0090>
- Alhazzani, K., Alotaibi, M. R., Alotaibi, F. N., Algerian, K., As Sobeai, H. M., Alhoshani, A. R., Alanazi, A. Z., Alanazi, W. A., & Alswayyed, M. (2021). Protective effect of valsartan against doxorubicin-induced cardiotoxicity: Histopathology and metabolomics in vivo study. *Journal of Biochemical and Molecular Toxicology*, 35(9), Article e22842. <https://doi.org/10.1002/jbt.22842>
- Ali, L. H., & Alkarbolii, M. M. (2024). Evaluation of the efficacy of Cordia myxa fruit on ISO-induced cardiotoxicity in male albino rats. *Tikrit Journal for Agricultural Sciences*, 24(4), 220–234. <https://doi.org/10.25130/tjas.24.4.18>
- Archer, S. (1993). Measurement of nitric oxide in biological models. *FASEB Journal*, 7(2), 349–360. <https://doi.org/10.1096/fasebj.7.2.8440411>
- Avagimyan, A., Pogosova, N., Kakturskiy, L., Sheibani, M., Challa, A., Kogan, E., Fogacci, F., Mikhaleva, L., Vandysheva, R., Yakubovskaya, M., Faggiano, A., Carugo, S., Urazova, O., Jahanbin, B., Lesovaya, E., Polana, S., Kirsanov, K., Sattar, Y., Trofimenko, A., Demura, T., Saghadzadeh, A., Koliakos, G., Shafie, D., Alizadehasl, A., Cicero, A., Costabel, J. P., Biondi-Zoccai, G., Ottaviani, G., & Sarrafzadegan, N. (2024). Doxorubicin-related cardiotoxicity: Review of fundamental pathways of cardiovascular system injury. *Cardiovascular Pathology*, 73, Article 107683. <https://doi.org/10.1016/j.carpath.2024.107683>

- Bancroft, J. D., & Gamble, M. (2008). *Theory and practice of histological techniques* (6th ed.). Elsevier Health Sciences.
- Bhutani, V., Varzideh, F., Wilson, S., Kansakar, U., Jankauskas, S. S., & Santulli, G. (2025). Doxorubicin-induced cardiotoxicity: A comprehensive update. *Journal of Cardiovascular Development and Disease*, 12(6), Article 207. <https://doi.org/10.3390/jcdd12060207>
- Cengiz, O., Baran, M., Balcioglu, E., Suna, P. A., Bilgici, P., Goktepe, O., Onder, G. O., Goc, R., & Yay, A. (2021). Use of selenium to ameliorate doxorubicin induced hepatotoxicity by targeting pro-inflammatory cytokines. *Biotechnic & Histochemistry*, 96(1), 67–75. <https://doi.org/10.1080/10520295.2020.1760353>
- Chaulin, A. M. (2023). The essential strategies to mitigate cardiotoxicity caused by doxorubicin. *Life*, 13(11), Article 2148. <https://doi.org/10.3390/life13112148>
- Cheah, I. K., Tang, R. M. Y., Wang, X., Sachaphibulkij, K., Chong, S. Y., Lim, L. H. K., Wang, J. W., & Halliwell, B. (2023). Protection against doxorubicin-induced cardiotoxicity by ergothioneine. *Antioxidants*, 12(2), Article 320. <https://doi.org/10.3390/antiox12020320>
- Eisvand, F., Imenshahidi, M., Ghasemzadeh Rahbardar, M., Tabatabaei Yazdi, S. A., Rameshrad, M., Razavi, B. M., & Hosseinzadeh, H. (2022). Cardioprotective effects of alpha-mangostin on doxorubicin-induced cardiotoxicity in rats. *Phytotherapy Research*, 36(1), 506–524. <https://doi.org/10.1002/ptr.7356>
- Hissin, P. J., & Hilf, R. (1976). A fluorometric method for determination of oxidized and reduced glutathione in tissues. *Analytical Biochemistry*, 74(1), 214–226. [https://doi.org/10.1016/0003-2697\(76\)90326-2](https://doi.org/10.1016/0003-2697(76)90326-2)
- Iftikhar, N., Hussain, A. I., Kamal, G. M., Manzoor, S., Fatima, T., Alswailmi, F. K., Ahmad, A., Alsuwayt, B., & Abdullah Alnasser, S. M. (2022). Antioxidant, anti-obesity, and hypolipidemic effects of polyphenol rich star anise (*Illicium verum*) tea in high-fat-sugar diet-induced obesity rat model. *Antioxidants*, 11(11), Article 2240. <https://doi.org/10.3390/antiox11112240>
- Karim, S., Pawar, R. S., Bagre, A., & Gaurav, A. (2023). Formulation, development and bioavailability profiling of *Illicium verum* (methanolic fraction). *European Journal of Biomedical and Pharmaceutical Sciences*, 10(7), 194–201. https://www.ejbps.com/ejbps/abstract_id/9538
- Khan, H. N., Rasheed, S., Choudhary, M. I., & Ahmed, N. (2022). Anti-glycation properties of *Illicium verum* Hook. f. fruit in-vitro and in a diabetic rat model. *BMC Complementary Medicine and Therapies*, 22, Article 79. <https://doi.org/10.1186/s12906-022-03550-z>
- Li, W., Wu, Z., Xia, Y., Tan, J., Zhao, H., Chen, S., Li, Y., Tang, H., Wang, G., Zhang, Y. (2022). Antiviral and antioxidant components from the fruits of *Illicium verum*


- Hook.f. (Chinese star anise). *Journal of Agricultural and Food Chemistry*, 70(12), 3697–3707. <https://doi.org/10.1021/acs.jafc.1c08376>
- Lin, X., Wu, G., Wang, S., & Huang, J. (2023). Bibliometric and visual analysis of doxorubicin-induced cardiotoxicity. *Frontiers in Pharmacology*, 14, Article 1255158. <https://doi.org/10.3389/fphar.2023.1255158>
- Linders, A. N., Dias, I. B., López Fernández, T., Tocchetti, C. G., Bomer, N., & Van der Meer, P. (2024). A review of the pathophysiological mechanisms of doxorubicin-induced cardiotoxicity and aging. *npj Aging*, 10, Article 9. <https://doi.org/10.1038/s41514-024-00135-7>
- Majali, I. S. (2022). Antioxidant and anti-inflammatory activity of star anise (*Illicium verum*) in murine model. *Biomedical and Pharmacology Journal*, 15(2), 1097–1108. <https://doi.org/10.13005/bpj/2445>
- Mohamed, H. K., Mobasher, M. A., Ebiya, R. A., Hassen, M. T., Hagag, H. M., El-Sayed, R., Abdel-Ghany, S., Said, M. M., & Awad, N. S. (2022). Anti-inflammatory, anti-apoptotic, and antioxidant roles of honey, royal jelly, and propolis in suppressing nephrotoxicity induced by doxorubicin in male albino rats. *Antioxidants*, 11(5), Article 1029. <https://doi.org/10.3390/antiox11051029>
- Mohammadabadi, M., Babenko, O., Borshch, O. O., Kalashnyk, O., Ievstafiiieva, Y., & Buchkovska, V. (2024). Measurement of the relative expression pattern of the UCP2 gene in different tissues of the Raini Cashmere goat. *Agricultural Biotechnology Journal*, 16(3), 317–332. <https://doi.org/10.22103/jab.2024.24337.1627>
- Mohammadabadi, M., Golkar, A., & Askari Hesni, M. (2023). The effect of fennel (*Foeniculum vulgare*) on insulin-like growth factor 1 gene expression in the rumen tissue of Kermani sheep. *Agricultural Biotechnology Journal*, 15(4), 239–256. <https://doi.org/10.22103/jab.2023.22647.1530>
- Mohanasundari, L., Brindha Devi, G. B., Saiyad Musthafa, M., & Madhavi, M. (2022). Effects of *Illicium verum* Hook. f. (Chinese herb) enriched diet on growth performance, immune response and disease resistance in *Catla catla* [Hamilton] fingerlings against *Aeromonas hydrophila*. *Fish & Shellfish Immunology*, 127, 455–462. <https://doi.org/10.1016/j.fsi.2022.06.050>
- Mulla, S., & Patil, S. B. (2025). A review on phytopharmacological profile of *Illicium verum* Hook. f. *Journal of Pharma Insights and Research*, 3, 66–74. <https://doi.org/10.69613/rkjesh66>
- Naderi, Y., Khosraviani, S., Nasiri, S., Hajiaghaei, F., Aali, E., Jamialahmadi, T., Banach, M., & Sahebkar, A. (2023). Cardioprotective effects of minocycline against doxorubicin-induced cardiotoxicity. *Biomedicine & Pharmacotherapy*, 158, Article 114055. <https://doi.org/10.1016/j.biopha.2022.114055>
- Patra, J. K., Das, G., Bose, S., Banerjee, S., Vishnuprasad, C. N., Del Pilar Rodriguez-Torres, M., & Shin, H. S. (2020). Star anise (*Illicium verum*): Chemical compounds,

- antiviral properties, and clinical relevance. *Phytotherapy Research*, 34(6), 1248–1267. <https://doi.org/10.1002/ptr.6614>
- Rawat, P. S., Jaiswal, A., Khurana, A., Bhatti, J. S., & Navik, U. (2021). Doxorubicin-induced cardiotoxicity: An update on the molecular mechanism and novel therapeutic strategies for effective management. *Biomedicine & Pharmacotherapy*, 139, Article 111708. <https://doi.org/10.1016/j.biopha.2021.111708>
- Sharafan, M., Jafernig, K., Ekiert, H., Kubica, P., Kocjan, R., Blicharska, E., & Szopa, A. (2022). *Illicium verum* (star anise) and trans-anethole as valuable raw materials for medicinal and cosmetic applications. *Molecules*, 27(3), Article 650. <https://doi.org/10.3390/molecules27030650>
- Sies, H., Belousov, V. V., Chandel, N. S., Davies, M. J., Jones, D. P., Mann, G. E., Murphy, M. P., Yamamoto, M., Winterbourn, C., et al. (2022). Defining roles of specific reactive oxygen species (ROS) in cell biology and physiology. *Nature Reviews Molecular Cell Biology*, 23(7), 499–515. <https://doi.org/10.1038/s41580-022-00456-z>
- Singh, S., & Verma, R. (2024). Comprehensive review on pharmacological potential of *Illicium verum*, Chinese herb. *Pharmacological Research - Modern Chinese Medicine*, 10, Article 100411. <https://doi.org/10.1016/j.prmcm.2024.100411>
- Syahputra, R. A., Harahap, U., Dalimunthe, A., Nasution, M. P., & Satria, D. (2022). The role of flavonoids as a cardioprotective strategy against doxorubicin-induced cardiotoxicity: A review. *Molecules*, 27(4), Article 1320. <https://doi.org/10.3390/molecules27041320>
- Tuseef, H., Raza, M. L., & Assad, T. (2021). Comparative evaluation of analgesic, antipyretic & anti-inflammatory effects of various extracts of dried fruit of *Illicium verum* Hook. f. (star anise) in rodents. *Walailak Journal of Science and Technology*, 18, Article 9456. <https://doi.org/10.48048/wjst.2021.9456>
- Vahabzadeh, M., Chamani, M. M., Dayani, O., Sadeghi, A. A., & Mohammadabadi, M. R. (2021). Effects of sweet marjoram (*Origanum majorana*) powder on growth performance, nutrient digestibility, rumen fermentation, meat quality and humoral immune response in fattening lambs. *Iranian Journal of Applied Animal Science*, 11(3), 567–576. <https://sanad.iau.ir/Journal/ijjas/Article/1023983>
- Wu, L., Wang, L., Du, Y., Zhang, Y., & Ren, J. (2023). Mitochondrial quality control mechanisms as therapeutic targets in doxorubicin-induced cardiotoxicity. *Trends in Pharmacological Sciences*, 44(1), 34–49. <https://doi.org/10.1016/j.tips.2022.10.003>
- Yang, E. C., Hsieh, Y. Y., & Chuang, L. Y. (2021). Comparison of the phytochemical composition and antibacterial activities of the various extracts from leaves and twigs of *Illicium verum*. *Molecules*, 26(13), Article 3909. <https://doi.org/10.3390/molecules26133909>

- Yilmaz, S., Kaya, E., Yonar, H., & Mendil, A. S. (2022). Doxorubicin-induced oxidative stress injury: The protective effect of kumiss on cardiotoxicity. *Journal of the Hellenic Veterinary Medical Society*, 73(4), 4545–4558. <https://doi.org/10.12681/jhvms.27822>
- Zhu, L., Luo, Y., Xiao, J., Hao, E., Wei, J., Zhao, J., Yao, C., Wang, Y., & Luo, H. (2024). Star anise (*Illicium verum* Hook. f.): Dual therapeutic and nutritional potential in food and medicine. *Acupuncture and Herbal Medicine*, 4(4), 563–587. <https://doi.org/10.1097/HM9.000000000000134>

بررسی اثرات محافظت‌کننده قلبی *Illicium verum* در برابر سمیت قلبی القا شده با

دوکسوروبیسین در رت‌ها

هیشم ل. عبد الهادی 

گروه زیست‌شناسی، دانشکده آموزش علوم پایه، دانشگاه الانبار، رمادی، استان الانبار ۳۱۰۰۱، عراق. ایمیل: haytham.lateif@uoanbar.edu.iq

تاریخ دریافت: ۱۴۰۴/۱۰/۲۰ تاریخ دریافت فایل اصلاح شده نهایی: ۱۴۰۴/۱۲/۱۵ تاریخ پذیرش: ۱۴۰۴/۱۲/۱۶

چکیده

هدف: دوکسوروبیسین (DOX) یکی از داروهای شیمی‌درمانی است که در سراسر جهان برای درمان بسیاری از سرطان‌ها استفاده می‌شود. با این حال، استفاده طولانی‌مدت از این دارو محدود است، زیرا می‌تواند باعث سمیت قلبی وابسته به دوز شود. این سمیت منجر به التهاب، آسیب به بافت قلب و افزایش استرس اکسیداتیو می‌گردد. بنابراین، هدف این مطالعه بررسی اثرات بالقوه محافظت‌کننده قلبی عصاره *Illicium verum* در برابر سمیت قلبی القا شده توسط DOX در رت‌ها بود.

مواد و روش‌ها: در این آزمایش چهار گروه از رت‌ها که به‌طور تصادفی انتخاب شده بودند مورد استفاده قرار گرفتند. این گروه‌ها شامل: گروه کنترل، گروه دریافت‌کننده DOX، گروه تیمار با عصاره *Illicium verum* با دوز ۱۰۰ میلی‌گرم بر کیلوگرم، و گروه تیمار با عصاره *Illicium verum* با دوز ۲۰۰ میلی‌گرم بر کیلوگرم بودند. عصاره به مدت ۷ روز به‌صورت خوراکی تجویز شد، سپس تزریق DOX انجام گرفت و پس از آن نیز عصاره به مدت ۷ روز به‌صورت خوراکی ادامه یافت. برای ارزیابی آسیب قلبی، نشانگرهای زیستی سرمی شامل تروپونین قلبی I (cTn-I)، کراتینیناز (CK-MB) و لاکتات دهیدروژناز (LDH) اندازه‌گیری شدند. همچنین برای تکمیل ارزیابی‌ها، سیتوکین‌های التهابی (IL-6 و TNF- α)، شاخص‌های استرس اکسیداتیو؛ مالون‌دی‌آلدئید (MDA) و مایلوپراکسیداز (MPO) و پارامترهای آنتی‌اکسیدانی شامل گلوتاتیون (GSH) و نیتریک اکسید (NO) اندازه‌گیری گردید. علاوه بر این، برای بررسی آسیب ساختاری بافت قلب، مطالعات هیستوپاتولوژیک نیز انجام شد.

نتایج: تزریق DOX باعث افزایش معنی‌دار آنزیم‌های قلبی، سیتوکین‌های التهابی و شاخص‌های استرس اکسیداتیو و همچنین کاهش سطح آنتی‌اکسیدان‌ها شد که نشان‌دهنده اثرات سمیت قلبی آن است. درمان با عصاره *Illicium verum* قبل از تزریق DOX، پارامترهای بیوشیمیایی مذکور را به‌صورت وابسته به دوز بهبود داد. بیشترین اثر محافظتی در گروه دریافت‌کننده دوز ۲۰۰ میلی‌گرم بر کیلوگرم مشاهده شد. در این گروه، سطح نشانگرهای آسیب قلبی و واسطه‌های التهابی در مقایسه با گروه DOX کمتر بود. همچنین در گروه‌های دریافت‌کننده عصاره، آسیب میوکاردی کاهش یافته، دژنراسیون سلولی کمتر شده و ساختار بافتی بهبود یافت.

نتیجه‌گیری: بر اساس نتایج این مطالعه، می‌توان پیشنهاد کرد که عصاره *Illicium verum* دارای اثرات محافظت‌کننده قابل توجهی در برابر سمیت قلبی القاشده توسط DOX است. این اثرات مثبت احتمالاً به دلیل خواص آنتی‌اکسیدانی و ضدالتهابی آن می‌باشد. بنابراین، ممکن است *Illicium verum* در کاهش آسیب قلبی مرتبط با درمان دوکسوروبیسین مفید باشد. با این حال، برای دستیابی به نتایج قطعی، انجام مطالعات گسترده‌تر ضروری است.

کلمات کلیدی: استرس اکسیداتیو، التهاب، سمیت قلبی، نشانگرهای زیستی قلبی، *Illicium verum*

نوع مقاله: پژوهشی

استناد: هیشم ل. عبد الهادی (۱۴۰۵) بررسی اثرات محافظت‌کننده قلبی *Illicium verum* در برابر سمیت قلبی القاشده با دوکسوروبیسین در رت‌ها. مجله بیوتکنولوژی کشاورزی، ۱۸(۳)، ۱۵۵-۱۷۶.

Publisher: Shahid Bahonar University of Kerman & Iranian

Biotechnology Society.

© the authors

